

Surgery Update

NEWS FROM THE MEDICAL COLLEGE OF WISCONSIN DEPARTMENT OF SURGERY

IN THIS ISSUE

- Breast Cancer Surgery and Reconstructive Options** 2
Amanda L. Kong, MD; Tina W.F. Yen, MD, MS; John B. Hijjawi, MD; John A. LoGiudice, MD
- Hyperparathyroidism and Minimally Invasive Parathyroidectomy** 3
Tracy S. Wang, MD, MPH
- Sphincter Sparing Techniques for Rectal Cancer** 4
Kirk A. Ludwig, MD
- The Stuart D. Wilson Chair** 5
- Pancreatic Cancer and the Whipple Procedure** 7
Douglas B. Evans, MD; Kathleen K. Christians, MD
- Clinical Trials: Pancreatic Cancer** 9
Anne Laulerkind, BSN, CCRC; Laura Burgardt, CMA

DEPARTMENT OF SURGERY

Dedicated to Clinical Care, Research and Education

- Cardiothoracic Surgery
 - Surgical Education
 - General Surgery
- Oral and Maxillofacial Surgery
 - Pediatric Surgery
 - Transplant Surgery
- Trauma Surgery and Critical Care
 - Vascular Surgery

Surgery Update is produced three times a year by The Medical College of Wisconsin – Department of Surgery, 9200 W. Wisconsin Ave., Milwaukee, WI 53226, © 2009.

Surgery Update is written for physicians for medical education purposes only. It does not provide a complete overview of the topics covered and should not replace the independent judgment of a physician about the appropriateness or risks of a procedure for a given patient.

Publication Manager: Tracy Milkowski, MBA



Message from the Chairman

Our goal is to provide you with periodic updates from our faculty on selected topics in clinical surgery and translational research.

By Douglas B. Evans, MD

*Donald C. Ausman Family Foundation Professor of Surgery
 Chairman, Department of Surgery, Medical College of Wisconsin*

In this issue, we discuss part one of a series on the contemporary management of localized breast cancer. We highlight which breast cancer patients are eligible for breast-conserving surgery versus mastectomy and who should receive immediate versus delayed post-mastectomy reconstruction. Tina W.F. Yen, MD, MS, and Amanda L. Kong, MD, received fellowship training in surgical oncology and breast surgery respectively, and bring a patient-focused multimodality approach to the care of breast cancer patients. John B. Hijjawi, MD, and John A. LoGiudice, MD, are accomplished microvascular reconstructive surgeons who offer all available breast reconstruction options.

Tracy S. Wang, MD, MPH, gives an overview of the surgical management of hyperparathyroidism (HPT) with reference to minimally invasive parathyroidectomy. Dr. Wang, who completed her endocrine surgery fellowship at Yale University School of Medicine, created a standardized “rapid” diagnostic protocol for referred HPT patients, including a complete confirmatory biochemical evaluation and a series of localization studies — all performed in less than two days. Accurate localization of the abnormal parathyroid gland is needed for a successful minimally invasive operation — usually an outpatient procedure.

Kirk A. Ludwig, MD, is board certified in colorectal surgery, an internationally known expert in the management of rectal cancer, and was recently awarded the Underwood Chair in colon cancer research. He reviews indications for sphincter sparing procedures for rectal cancer patients and describes the complex anatomy and physiology of the mid-low rectum and anus. For many with rectal cancer, functional outcome and oncologic result is dependent on accurate staging, use of contemporary combined modality treatment, and the experience of the surgeon, as operations in the low pelvis are difficult and the anatomy unfamiliar to those not specifically trained in creating low rectal anastomoses.

Finally, Kathleen K. Christians, MD, and I discuss the controversial topic of vascular resection and the Whipple procedure for pancreatic cancer patients. As for other topics in this issue, the surgical procedure is one piece of a successful treatment program that includes high-quality diagnostic imaging and the frequent application of systemic therapy and local-regional chemoradiation.

We hope you find *Surgery Update* interesting and helpful. If there are topics you would like discussed in the future, please e-mail me: devans@mcw.edu. Thank you for supporting the Medical College of Wisconsin Department of Surgery.

Froedtert & The Medical College of Wisconsin • mcw.edu/surgery

Referrals: 800-272-3666 • Transfers/Consultations: 877-804-4700

Clinical Cancer Center — Referrals/Transfers/Consultations: 866-680-0505

Children’s Hospital of Wisconsin — Referrals/Transfers/Consultations: 800-266-0366



Philip N. Redlich, MD, PhD, chief of the Division of Surgical Education will be coordinating the efforts for the Surgical Skills Center.

Ausman Foundation Makes Major Donation to Surgical Education

The Medical College of Wisconsin Department of Surgery is pleased and excited to announce that Robert Ausman, MD, and his family have donated \$100,000 from the Ausman Foundation toward the development of a surgical skills center. The role of the surgical skills lab in residency training has become increasingly important with the focus on attaining a level of competency in performing procedures in a simulated environment (prior to the operating room). There has been an explosion of interest in simulators, from simple laparoscopic training boxes to complex computerized machines that allow repeated practice of common procedures with increasing authenticity. The recent announcement that passage of the Fundamentals of Laparoscopic Surgery course is required to achieve board certification is an example of the increasing importance of skills training during residency. Facilities with a dedicated skills lab for such training are key to the development of competent surgeons. The donation by the Ausman Foundation is the first step toward achieving the goal of a world-class surgical skills center at the Medical College of Wisconsin Department of Surgery.

BREAST CANCER SURGERY AND RECONSTRUCTIVE OPTIONS

The Breast Care Center at the Froedtert & The Medical College of Wisconsin Clinical Cancer Center provides an interdisciplinary approach to breast cancer treatment in a state-of-the-art cancer center. Please visit froedtert.com/cancer for more information on our facility.

By **Amanda L. Kong, MD**, Assistant Professor of Surgery; **Tina W.F. Yen, MD, MS**, Assistant Professor of Surgery; **John B. Hijjawi, MD**, Assistant Professor of Plastic and Reconstructive Surgery; and **John A. LoGiudice, MD**, Assistant Professor of Plastic and Reconstructive Surgery

Our interdisciplinary team consists of surgeons, radiologists, radiation oncologists, medical oncologists, genetic counselors, pathologists and plastic surgeons. When women consult with one of our breast surgeons, surgical options are discussed and tailored around the patient's cancer and her desires. Breast surgery options include breast conserving surgery (BCS) or mastectomy.

Who is eligible for BCS vs. mastectomy?

BCS, also known as lumpectomy or segmental mastectomy, consists of removing part of the breast to include the cancer with a rim of normal tissue around it. All patients considering lumpectomy meet with a radiation oncologist pre-operatively to discuss radiation therapy, which is typically administered five days a week for six weeks. Almost all patients who undergo BCS require post-lumpectomy radiation therapy to the remaining breast tissue. With the addition of radiation therapy after lumpectomy, 10-year local recurrence rates are reduced to less than 10 percent versus 25 percent to 30 percent without radiation therapy. For patients with invasive disease, the axilla is evaluated with sentinel lymph node biopsy if lymph nodes are not palpable, or if fine needle aspiration of a palpable node is negative or inconclusive prior to undergoing surgery. If the sentinel node biopsy is positive for malignancy, a completion axillary dissection is performed. For patients with biopsy-proven axillary lymph node involvement prior to surgery, an axillary lymph node dissection is performed at the time of breast surgery.

Patients with Stage 0 (ductal carcinoma in situ) and early stage breast cancer (Stage I and II) are usually eligible for BCS. Select Stage III patients may also be eligible for BCS. These patients receive neoadjuvant chemotherapy

prior to surgery. If the patient responds well to chemotherapy and the tumor decreases in size, the patient may be a candidate for BCS.

In certain situations, mastectomy is indicated. These cases include: multicentric or extensive disease, locally advanced breast cancer, prior chest wall irradiation, inflammatory breast cancer, inability to achieve negative margins with BCS, inability/refusal to receive post-lumpectomy radiation treatment, and inability to perform BCS with a decent cosmetic result due to a large tumor size relative to breast size.

If a patient is a mastectomy candidate, she is offered the opportunity to meet with a plastic surgeon to discuss post-mastectomy reconstructive options prior to making her final decision regarding her surgical plan. The Women's Health and Cancer Rights Act of 1998 is a U.S. federal law that requires commercial health insurance companies to cover breast reconstruction after breast cancer surgery at any time and considers surgery on the opposite breast to improve breast symmetry to be part of breast reconstruction.

Who should get immediate vs. delayed post-mastectomy reconstruction?

About half of American women who pursue breast reconstruction do so at the time of mastectomy (immediate reconstruction), while the other half undergo reconstruction several months or even years after mastectomy (delayed reconstruction). Coordination of surgery, chemotherapy and, when necessary, post-mastectomy radiation therapy is carefully arranged at Froedtert & The Medical College through our interdisciplinary Breast Cancer Program team. As a result, more treatment options may be available.

If a woman desires post-mastectomy reconstruction, the most important issue to determine pre-operatively is whether she will require post-mastectomy radiation therapy. Post-mastectomy radiation therapy is typically reserved for women at high risk for locally recurrent disease. Currently, post-mastectomy radiation therapy is recommended to women who have Stage III or Stage IIB disease defined as:

continued on page 8

PRIMARY HYPERPARATHYROIDISM AND MINIMALLY INVASIVE PARATHYROIDECTOMY

The evolution of parathyroid surgery is an interesting tale of science and serendipity and can be roughly divided into two eras: the discovery of parathyroid function and its effects on human pathophysiology, and the advancement of parathyroid hormone measurement and surgical techniques for parathyroidectomy.

By Tracy S. Wang MD, MPH
Assistant Professor of Surgery

The parathyroid gland was first described in 1848, when a London anatomist, Sir Richard Owen, found "...a small, compact, yellow glandular body that is attached to the thyroid where the veins emerge" in the cadaver of an Indian rhinoceros. Over the next 75 years, scientists and clinicians worked to elucidate the anatomy and physiology of the parathyroid gland. The effects of the parathyroid gland on bone disease and, in the early years of thyroid surgery, postoperative hypocalcemia, were clarified, leading William Halstead to remark, "it seems hardly credible that the loss of bodies so tiny as the parathyroids should be followed by a result so disastrous."

The last 75 years have been no less remarkable in the evolution of parathyroid surgery and the minimally invasive parathyroidectomy. While the first parathyroidectomy was performed in 1925 by a Viennese surgeon named Felix Mandl, perhaps the most famous case is that of Captain Charles Martell. Captain Martell was a sea captain who suffered the debilitating effects of bone loss and who, between 1926-1932, underwent six failed surgical explorations. Captain Martell read extensively on his disease and finally demanded that his surgeons explore his mediastinum, where he correctly believed the missing parathyroid adenoma to be. With the discovery of parathyroid hormone in the 1920s and the development of radioimmunoassays in the 1960s, parathyroid surgery was truly revolutionized.

Primary Hyperparathyroidism

Primary hyperparathyroidism (pHPT) is defined as hypercalcemia associated with the inappropriate elevation of parathyroid hormone (PTH) levels. The incidence in the United States is 25-30 cases per 100,000 people and it affects women three times more often than men. Classically, patients with pHPT presented with nephrolithiasis, peptic ulcer disease, and/or severe bone disease. Increasingly, however, the diagnosis is made after the incidental detection of elevated serum

calcium levels, and patients have few, if any, classic symptoms of disease.

The Third International Workshop on the Management of Asymptomatic Hyperparathyroidism convened in 2008 and recently published its revised guidelines. Indications for surgery in patients with asymptomatic disease now include: (1) serum calcium >1.0 mg/dL above the upper limits of normal; (2) GFR < 60 ml/min; (3a) bone mineral density T-scores <-2.5 in postmenopausal women and men >50 years; (3b) bone mineral density Z-scores <-2.5 in premenopausal women and men <50 years; (4) age <50 years; and (5) any patient in whom medical management may not be desired or possible.

A major change from the previous 2002 guidelines is the removal of a 24-hour urinary calcium >400 mg/24 hours as an indication for surgery in the asymptomatic patient. Surgery remains the only curative treatment for pHPT, as the use of bisphosphonates and calcimimetics are not currently indicated for treatment.

Minimally Invasive Parathyroidectomy

For a long time, bilateral cervical exploration was the gold standard for parathyroidectomy and included visualization of all parathyroid glands prior to excision of the adenoma. Success rates were greater than 95 percent, with minimal morbidity. However, 85 percent to 90 percent of cases of pHPT are due to a solitary parathyroid adenoma, calling into question the need for routine bilateral cervical exploration. With the advent of the intraoperative parathyroid hormone (IOPTH) assay and improved imaging techniques, a focused uniglandular exploration, namely minimally invasive parathyroidectomy (MIP), became possible.

The success rate of MIP is comparable to that of bilateral exploration. Advantages of MIP include shorter operative time, decreased length of stay and decreased complication rates, including recurrent laryngeal nerve injury and hypoparathyroidism. Select patients can undergo MIP with IV sedation and local anesthesia using a surgeon-administered cervical block. Most patients are able to be discharged on the day of surgery.

Preoperative Imaging

MIP is contingent on successful preoperative localization studies, including sestamibi, ultrasonography and CT scans. At Froedtert & The Medical College of Wisconsin, all patients undergo an imaging protocol of same-day sestamibi with single photon electron computed tomography (SPECT), ultrasonography and angiographic CT, if necessary.

Sestamibi scans rely on the uptake of the sestamibi isotope technetium 99m-sestamibi. While initially present in thyroid and parathyroid tissue, Tc99m-sestamibi quickly washes out of thyroid tissue, but is retained within an abnormal parathyroid gland. Using the double phase technique of immediate and delayed imaging, the abnormal parathyroid gland is readily visualized. The addition of a three-dimensional aspect to sestamibi scans, SPECT, enhances the detection of abnormal parathyroid glands. Sensitivity of sestamibi scanning for detecting solitary adenomas ranges from 50 percent to 80 percent.

An adjunct to sestamibi scanning for preoperative localization is ultrasonography. Sensitivity for parathyroid localization in patients with sporadic primary hyperparathyroidism ranges from 57 percent to 77 percent; the combination of sestamibi and ultrasonography increases the percentage of correctly identified glands as high as 90 percent. Disadvantages to ultrasound include decreased sensitivities in patients with multiglandular hyperplasia and with ectopic glands, particularly those located retroesophageally or in the mediastinum. Ultrasonography also allows the detection of thyroid nodules that may require further evaluation prior to surgery.

At some institutions, the use of angiographic CT scans has been added to the armamentarium of preoperative localization studies. In a recent study, angiographic CT scans demonstrated improved sensitivity (88 percent) over sestamibi imaging and ultrasound when the imaging studies were used to localize hyperfunctioning parathyroid glands to one side of the neck and even to the correct quadrant (e.g., right/left inferior/superior) of the neck (sensitivity, 70 percent

continued on page 8

SPHINCTER SPARING TECHNIQUES FOR RECTAL CANCER

What physicians and patients should understand is that in high-volume centers and in the hands of high volume rectal cancer surgeons, sphincter sparing techniques are utilized for more than 80 percent of patients.

By Kirk A. Ludwig, MD
Associate Professor of Surgery

A major issue facing patients with newly diagnosed rectal cancer is the prospect that treatment means a permanent colostomy. This is not an unreasonable fear, since recent data indicate that for the majority of rectal cancer patients in the United States, sphincter sparing techniques are not utilized. This is unfortunate.

Specialty training is a major factor in the ability of a surgeon to offer a sphincter sparing option. We view fellowship training in colorectal surgery as crucial. This training emphasizes an in-depth understanding of the complex anorectal anatomy hidden in the confines of the deep, dark pelvis. Key anatomic structures are the mesorectum and its fascia propria, Denonvillier's and Waldeyer's fascia, the pelvic autonomic nerves, and the intricate anatomic relationship of the pelvic floor and the internal and external anal sphincters. Specialty training also gives the colorectal surgeon a detailed understanding of the physiology of continence and defecation. As a result of managing these functional issues on a daily basis and understanding how various operations affect these functions, the colorectal surgeon has the kind of insight needed to not only choose the appropriate approach to treat a rectal cancer in any one patient, but to also manage any continence or defecatory dysfunction that may result. Without a thorough understanding of the anatomy and physiology and the reconstructive techniques that can be utilized, many surgeons cannot offer state-of-the-art sphincter sparing options.

Modern sphincter sparing techniques for rectal cancer are based on a detailed understanding of tumor biology, rectal anatomy, accurate staging of the tumor using the latest in rectal ultrasound and MRI technology and finally, a thorough grasp of what can be accomplished using an interdisciplinary approach. At the Froedtert & The Medical College of Wisconsin Clinical Cancer Center, patients with rectal cancer are managed in an interdisciplinary clinic with input from colorectal surgery, medical oncology and radiation therapy. Colleagues from gastroenterology, radiology and surgical oncology complete the team. At each level, the latest techniques are utilized to optimize oncologic

outcomes and to preserve function and quality of life. From a surgical standpoint, sphincter sparing techniques might involve transanal excision, transanal endoscopic microsurgery (TEM) or ultimately, a formal open or laparoscopic low anterior resection with reconstruction using a colonic pouch to replace the rectum. Even advanced tumors located in proximity to the dentate line can be treated with a sphincter sparing resection known as an intersphincteric resection with colonic pouch to anal anastomosis. By whatever method, less than 20 percent of our rectal cancer patients require a permanent colostomy. Patients who are told they need a permanent colostomy for treatment of their rectal cancer should seek a second opinion. There is usually an oncologically sound way to avoid the colostomy.

Why is there such a discrepancy in what can be done (with sphincter preservation) and what is often done? In addition to the issues outlined above, it probably has much to do with the volume of rectal cancer surgery seen by the average surgeon. In 2005, using a large national database, we published data showing that rectal cancer patients treated by high volume surgeons (> 10 rectal cancer surgeries per year) are five times more likely to undergo sphincter-sparing procedures than those treated by low volume surgeons (one to three rectal cancer surgeries per year). In this time of greater sub-specialization, surgeons who operate on all parts of the body simply do not see patients with mid- and low-rectal cancers often enough to develop the necessary expertise to allow for routine sphincter preservation. This is because it is technically easier to remove the sphincter apparatus than to preserve it. Indeed, data which have examined rectal cancer surgical volume for general surgeons in the United States have clearly demonstrated that most surgeons have limited experience with complex low rectal pelvic surgery.

Currently, various organizations are struggling with the complex issue of specialty surgery: which surgeons should do which operations? In Europe and Asia, they have concluded that rectal cancer surgery is a specialty operation that should no longer be in the hands of every surgeon. While current data from the United States has not specifically addressed the volume and oncologic outcome relationship, it appears too many sphincters are being sacrificed, and that the odds of this outcome are highest with low-volume surgeons.


Based on what has been shown regarding the relationship between volume and outcome with pancreatic and esophageal cancer, it is reasonable to assume that the mid- and low-rectum may have a similar story. The complex anatomy of the pelvis combined with the technical challenges of sphincter preservation make this region of the body the territory of the subspecialist. The complexity of patient management is further magnified by the added importance of combining chemotherapy and radiation in those with rectal cancer; such treatment sequencing must maximize treatment response while minimizing toxicity.

For More Information or an Appointment

For further information, please refer to the Department of Surgery Web site at mcw.edu/surgery. To schedule an appointment, please call the Froedtert & The Medical College of Wisconsin Clinical Cancer Center at 414-805-0505 or 866-680-0505.

References:

1. Ricciardi R, Virnig BA, Madoff RD, Rothenberger DA, Baxter NN. The status of radical proctectomy and sphincter-sparing surgery in the United States. *Dis Colon Rectum* 2007;50:1119-27.
2. Ludwig KA MC. The status of radical proctectomy and sphincter-sparing surgery in the United States. Invited Commentary. *Dis Colon Rectum* 2007;50:1126-7.
3. Purves H, Pietrobon R, Hervey S, Guller U, Miller W, Ludwig K. Relationship between surgeon caseload and sphincter preservation in patients with rectal cancer. *Dis Colon Rectum* 2005;48:195-202; discussion -4.
4. Hyman N. How much colorectal surgery do general surgeons do? *J Am Coll Surg*. 2002;194:37-39.
5. Dimick JB, et al. Measuring surgical quality: what's the role of provider volume? *World J Surg* 2005;29:1217-1221.
6. Haward RA, Morris E, Monson JR, Johnston C, Forman D. The long-term survival of rectal cancer patients following abdominoperineal and anterior resection: results of a population-based observational study. *Eur J Surg Oncol* 2005;31:22-8.



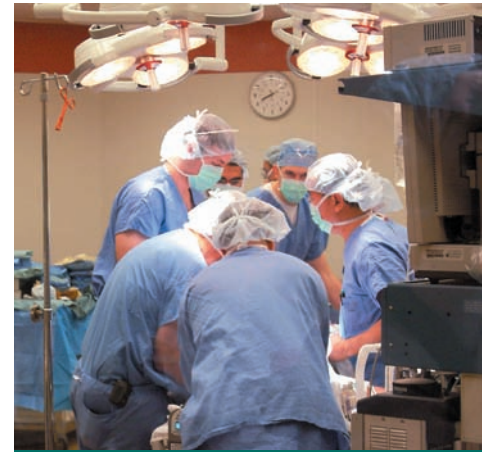Stuart D. Wilson, MD

STUART D. WILSON CHAIR IN SURGICAL ONCOLOGY

With great pride and admiration for its namesake, the Department of Surgery at the Medical College of Wisconsin announces the creation of the Stuart D. Wilson Chair in Surgical Oncology.

Recruitment is underway for chief of the newly established Division of Surgical Oncology, who will be the inaugural holder of the Stuart D. Wilson Chair. Dr. Wilson is an active faculty member of the Department of Surgery and an internationally known expert in oncologic and endocrine surgery. He graduated from the University of Illinois College of Medicine in 1960. He completed his surgical training in the Marquette University Integrated Residency and the Milwaukee County General Surgery Training Program in 1966 under direction of Edwin Ellison, MD. Dr. Wilson joined the Medical College of Wisconsin as a professor of surgery in 1979. His tenure at the Medical College was interrupted only for service in the Vietnam War from 1968 to 1969, where he received the Bronze Star with Combat V. Dr. Wilson has been president of the Milwaukee Academy of Surgery, the Milwaukee Surgical Society, the Wisconsin Surgical Society, and in 1991, was president of the American

Association of Endocrine Surgeons. He has also served two terms as governor at large (Wisconsin) of the American College of Surgeons. Dr. Wilson has made many seminal contributions to published literature on diseases of the pancreas, extrahepatic bile ducts and endocrine system. His work with Dr. Ellison on the Zollinger-Ellison Syndrome is internationally recognized. Dr. Wilson has published more than 100 peer-reviewed manuscripts, more than 25 book chapters, and has made numerous international presentations. He has trained surgeons throughout Wisconsin and the Midwest. There is no higher honor in the Medical College Department of Surgery than the creation of an endowed chair. Dr. Wilson is a gifted clinician, dedicated researcher and teacher and a wonderful human being.



To refer a patient or request a transfer or consultation, please use these numbers:

Froedtert &
The Medical College of Wisconsin

Referrals: 800-272-3666

Transfers/Consultations:

877-804-4700

mcw.edu/surgery

Clinical Cancer Center
Referrals/Transfers/Consultations:

866-680-0505

Children's Hospital of Wisconsin
Referrals/Transfers/Consultations:

800-266-0366

DEPARTMENT OF SURGERY DIVISION CHIEF, SURGICAL ONCOLOGY

The Department of Surgery, Medical College of Wisconsin, has an immediate opening for the position of chief, Division of Surgical Oncology.

The selected candidate will be the Stuart D. Wilson Professor of Surgery. In addition to the endowed professorship, the position is supported by a generous start-up package and a new office suite in the recently completed Froedtert & The Medical College of Wisconsin Clinical Cancer Center. Completion of an SSO-approved fellowship and demonstrated achievement in basic or clinical research is required. Candidates will need to qualify for the rank of associate or full professor at the Medical College of Wisconsin. The Division of Surgical Oncology is responsible for academic program development in the areas of breast, endocrine, HPB, upper GI and melanoma/sarcoma oncology. The Department of Surgery welcomes interested candidates,

as well as recommendations from senior clinicians/investigators. Interested applicants should submit a letter of interest and curriculum vitae to:

Tina W.F. Yen, MD, MS, Chair, Search Committee

Douglas B. Evans, MD, Chairman

Department of Surgery
Medical College of Wisconsin
9200 West Wisconsin Ave.
Milwaukee, Wisconsin 53226

E-mails: tyen@mcw.edu; devans@mcw.edu
EOE M/F/D/V

Medical College of Wisconsin Department of Surgery

LIST OF FACULTY AND SPECIALTIES

ACUTE CARE SURGERY, TRAUMA AND CRITICAL CARE

Marshall A. Beckman, MD
Karen J. Brasel, MD, MPH
Panna A. Codner, MD
Lewis B. Somberg, MD
Travis P. Webb, MD
John A. Weigelt, MD, DVM, MMA

ADULT CARDIAC SURGERY

G. Hossein Almassi, MD
R. Eric Lilly, MD
Saqib Masroor, MD, MHS
Alfred C. Nicolosi, MD

BARIATRIC AND MINIMALLY INVASIVE SURGERY

James R. Wallace, MD, PhD

BREAST SURGERY

Amanda L. Kong, MD
Alonzo P. Walker, MD
Tina W.F. Yen, MD, MS

COLORECTAL SURGERY

Lauren A. Kosinski, MD, MS
Kirk A. Ludwig, MD
Mary F. Otterson, MD, MS

COMMUNITY GENERAL SURGERY

Marshall A. Beckman, MD
Dean E. Klinger, MD

ENDOCRINE SURGERY

Douglas B. Evans, MD
Tracy S. Wang, MD, MPH
Stuart D. Wilson, MD
Tina W.F. Yen, MD, MS

GENERAL SURGERY

Marshall A. Beckman, MD
Karen J. Brasel, MD, MPH
Kathleen K. Christians, MD
Panna A. Codner, MD
Alysandra Lal, MD
Edward J. Quebbeman, MD, PhD
Theresa M. Quinn, MD
Philip N. Redlich, MD, PhD
Lewis B. Somberg, MD
Gordon L. Telford, MD
Alonzo P. Walker, MD
James R. Wallace, MD, PhD
Travis P. Webb, MD
John A. Weigelt, MD, DVM, MMA

GENERAL THORACIC SURGERY

Mario G. Gasparri, MD
George B. Haasler, MD
Daryl P. Pearlstein, MD
William B. Tisol, MD

HEPATIC PANCREATIC- BILIARY SURGERY

Kathleen K. Christians, MD
Douglas B. Evans, MD
Sam G. Pappas, MD
Edward J. Quebbeman, MD, PhD
Stuart D. Wilson, MD

ORAL AND MAXILLOFACIAL SURGERY

Jill N. Merrill, DDS
Lee M. Radke, DDS
Mary Lou C. Sabino, DDS
Steven R. Sewall, DDS

PEDIATRIC GENERAL AND THORACIC SURGERY

John J. Aiken, MD
Marjorie J. Arca, MD
Casey M. Calkins, MD
David M. Gourlay, MD
Dave R. Lal, MD
Keith T. Oldham, MD
Thomas T. Sato, MD
Andrea L. Winthrop, MD

PEDIATRIC CARDIOTHORACIC SURGERY

Kimberly L. Gandy, MD, PhD
Michael E. Mitchell, MD
James S. Tweddell, MD

TRANSPLANT SURGERY

David C. Cronin, II, MD, PhD
Christopher P. Johnson, MD
Allan M. Roza, MD
Brian D. Shames, MD

VASCULAR SURGERY

Kellie R. Brown, MD
James B. Gosset, MD
(Vascular Medicine)
Brian D. Lewis, MD
Gary R. Seabrook, MD

BASIC SCIENCE

John Baker, PhD
(Cardiothoracic Surgery)
Laura Cassidy, PhD
(Pediatric Surgery)
Rebecca C. Cogwell Anderson, PhD
(Transplant Surgery)
Terri deRoos-Cassini, PhD
(Trauma Surgery/Critical Care)
Adrianus Domen, PhD
(Cardiothoracic Surgery)
Charles E. Edmiston Jr., PhD, MS,
CIC (Vascular Surgery)
Qing Miao, PhD
(Pediatric Surgery)
Aoy Mitchell, PhD
(Cardiothoracic Surgery)
Vani Nllakantan, PhD
(Transplant Surgery)
Galen Pieper, PhD
(Transplant Surgery)
Kirkwood Pritchard, PhD
(Pediatric Surgery)
Parvaneh Rafiee, PhD
(General Surgery)
Yang Shi, PhD
(Pediatric Surgery)
Toku Takahashi, MD, PhD
(General Surgery)
Sarah Trost, PhD
(Transplant Surgery)
Hao Xu, PhD
(Pediatric Surgery)

CONTRIBUTORS *Many thanks to the physicians and staff who contributed to this issue of Surgery Update.*



Laura Burgardt, CMA



Kathleen K. Christians, MD



John B. Hijjawi, MD



Amanda L. Kong, MD



Anne Laulederkind, BSN, CCRC



John A. LoGiudice, MD



Kirk A. Ludwig, MD



Sam G. Pappas, MD



Tracy S. Wang, MD, MPH



Tina W.F. Yen, MD, MS

THE WHIPPLE PROCEDURE: RESECTION OF THE SUPERIOR MESENTERIC AND/OR PORTAL VEIN AT THE TIME OF PANCREATODUODENECTOMY

Dr. A.O. Whipple described the operation that bears his name in 1935 and in 1946, Waugh and Clagett modified the Whipple operation to a procedure very similar to that which is done today.

By **Douglas B. Evans MD**, *Chairman, Department of Surgery*; and **Kathleen K. Christians, MD**, *Associate Professor of Surgery*

Most importantly, Waugh and Clagett outlined the goals of surgical therapy for pancreatic cancer: (1) there should be a reasonable opportunity for cure; (2) the risk of death should not outweigh the prospects for cure; and (3) the patient should be left in as normal a condition as possible. The debate over whether major vascular resection should be performed at the time of pancreatotomy should be considered with these goals in mind. Clearly, surgeons who perform such extended operations should be able to do them safely and patients should be selected carefully based upon the biology of the disease and the general health of the patient. Fortunately, in the current era of more effective systemic therapies and the ability to deliver radiation therapy in a more targeted fashion (thereby reducing toxicity), we can carefully select those patients in whom the risk of a major operation can be justified (refer to bibliography supplied by Dr. Evans at froedtert.com/evans.)

In contrast to tumor-artery (celiac axis, hepatic artery, superior mesenteric artery) abutment, which can be accurately interpreted on good-quality CT imaging, tumor abutment of the lateral or posterolateral wall of the superior mesenteric vein (SMV) or the superior mesenteric-portal vein (SMPV) confluence may not always be appreciated on preoperative imaging. Because of this, surgeons without the technical ability to perform venous resection may be in the position of being unable to separate the SMV from the tumor predisposing to an incomplete resection or an inadvertent venotomy. Importantly, deformity of the vein wall at the tumor interface (figure 1), even if subtle, often indicates tumor adherence. This may only be appreciated if CT images are performed with a venous phase of contrast enhancement and are accurately interpreted. When vascular resection and reconstruction are performed by experienced surgeons at institutions where such surgery is frequently done, morbidity and mortality are not increased compared to a standard whipple procedure without vascular resection.

It is generally felt that surgical resection of the primary tumor is necessary to cure the patient with pancreatic cancer, even if often not sufficient. (Chemotherapy and radiation are also very important components of a successful treatment program.) Indeed, for those patients who are deemed unresectable due to local tumor extension to adjacent blood vessels, the median survival is 10 to 12 months. In contrast, if the primary tumor can be resected (to include adjacent vessels when necessary), median survival is two to three years and almost one-third of such patients survive five years from the time of diagnosis. Resection of the SMV or SMPV confluence can be performed with or without ligation of the splenic vein and may require an interposition graft (left internal jugular vein most frequently used; see figure 2) or a patch (saphenous vein). We usually use inflow occlusion of the superior mesenteric artery (SMA) to prevent bowel edema, which may complicate the post-resection pancreatic and biliary reconstructions. Importantly, at Froedtert & The Medical College of Wisconsin, all patients are evaluated in an interdisciplinary fashion by experts in diagnostic radiology, gastroenterology, medical oncology, radiation oncology and surgery. For the pancreatic cancer patient, surgery is just one part of a successful treatment program.

Additional information may be found in the following references, which are available in PDF format by visiting froedtert.com/evans. Patients with pancreatic cancer can be referred to Froedtert & The Medical College by calling our referral specialist Gail Laschen at 414-805-6849.

References

1. Von Hoff DD, Evans DB, Hruban RH. Pancreatic Cancer. Sudbury, MA: Jones and Bartlett, 2005.
2. Katz MHG, et al. Anatomy of the superior mesenteric vein with special reference to the surgical management of first-order branch involvement at pancreaticoduodenectomy. *Ann Surg.* 2008;248(6):1098-102.
3. Tseng, et al. Pancreaticoduodenectomy with vascular resection: margin status and survival duration. *J Gastrointest Surg* 2004;8:935-49.

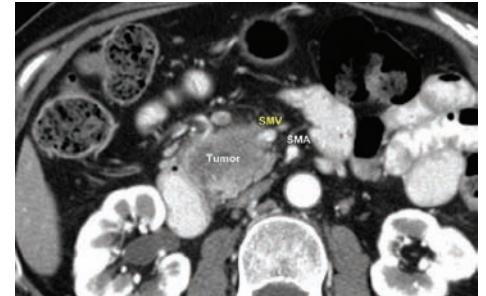


Figure 1

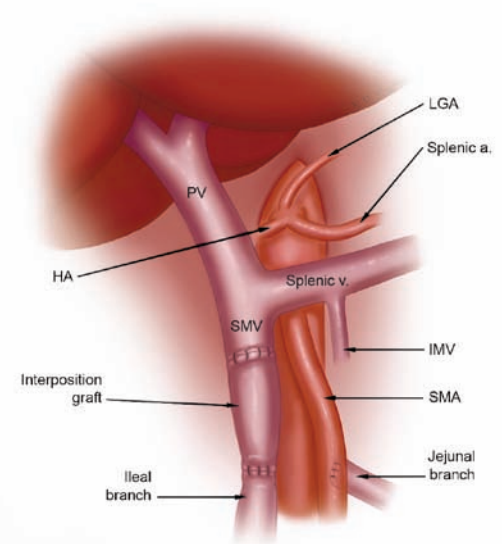


Figure 2

Visual Art: © 2008 The University of Texas M.D. Anderson Cancer Center.

Coming This Fall: CME CREDITS ONLINE

Earn CME credits and stay in touch at a time of your choosing by attending Grand Rounds online without leaving your home or office. Please consider us for convenient, comprehensive, quality learning at mcw.edu/surgery. We are a link to your "surgery home." Watch for further announcements in this newsletter.

BREAST CANCER ... *continued from page 2*

(1) tumors 5 cm or larger (T3), (2) > 4 positive axillary lymph nodes, or (3) skin or chest wall involvement. Women with one to three positive axillary lymph nodes are considered for post-mastectomy radiation therapy on an individual basis. If post-mastectomy radiation therapy is planned, reconstruction can be performed in a delayed fashion, usually six to 12 months after radiation therapy is completed, given the side effects of radiation therapy on the skin and subcutaneous tissues. Another option is to perform a delayed-immediate reconstruction, which consists of a temporary implant placement at the time of the skin-sparing mastectomy.

Delayed-immediate reconstruction is also utilized when final pathology results will determine the need for radiation therapy (largely Stage II patients). A skin-sparing mastectomy involves removal of the entire breast through a small incision that typically removes only the nipple-areolar complex, thereby sparing all of the woman's skin. The tissue expander is placed as a temporizing measure to preserve the skin-sparing mastectomy's envelope of skin. If radiation therapy is recommended, the expander may be left in place during radiation and the formal, permanent reconstruction can then be performed approximately six to 12 months after radiation therapy is completed.

If it is determined that radiation therapy is not necessary, the patient may undergo her permanent reconstruction approximately two weeks after initial surgery.

For patients who are not anticipated to require post-mastectomy radiation (Stage 0, I and most Stage IIA women), immediate reconstruction after a skin-sparing mastectomy can be performed. Of course, patients may choose not to have breast reconstruction at all. These women can use an external breast prosthesis. This is a silicone or foam breast form that is placed within a bra or contained within a specialized post-mastectomy bra.

Whether a patient desires reconstruction at the time of mastectomy or years later, or even desires revision of a previous attempt at reconstruction, it is virtually always possible to find a reconstructive option that will work for her. Previous limitations like radiation therapy or abdominal surgery are rarely a barrier to reconstruction for women today. These options are available largely as the result of a commitment to coordinated care that is the hallmark of our Breast Cancer Program team. All post-mastectomy reconstructive options offered at Froedtert & The Medical College will be discussed in the next issue of this newsletter.

For More Information or an Appointment

For more information or to arrange a consultation with one of our breast surgeons, please call 414-805-0505 or 866-680-0505. To arrange a consultation with one of our plastic surgeons specializing in breast reconstruction, please call 414-805-5440.

References

1. National Comprehensive Cancer Network. NCCN Clinical Practice Guidelines in Oncology™. http://www.nccn.org/professionals/physician_gls/f_guidelines.asp
2. Hammer C, Fanning A, Crowe J. Overview of breast cancer staging and surgical treatment options. *Cleve Clin J Med.* 2008 Mar; 75 Suppl 1: S10-6.
3. Buchholz, T. Radiation Therapy for Early-Stage Breast Cancer after Breast-Conserving Surgery. *N Engl J Med* 2009; 360: 63-70.
4. Chevray PM. Timing of breast reconstruction: immediate versus delayed. *Cancer J* 2008; 14: 223-229.
5. Kronowitz SJ and Kuerer HM. Advances and surgical decision-making for breast reconstruction. *Cancer* 2006; 107: 893-907.
6. Cordeiro PG. Breast reconstruction after surgery for breast cancer. *N Engl J Med* 2008; 359: 1590-1601.

PRIMARY HYPERPARATHYROIDISM ... *continued from page 3*

vs. sestamibi, 33 percent and ultrasound, 29 percent). Angiographic CT scans have been shown to be particularly useful in the localization of abnormal parathyroid glands in patients with persistent or recurrent hyperparathyroidism.

Intraoperative parathyroid hormone monitoring

The half-life of PTH is three to four minutes. Using the rapid IOPTH assay, serum PTH levels can be measured while the patient is in the operating room, with a turnaround time of approximately 15 minutes. A decrease in IOPTH of >50 percent from the baseline (pre-excision) level and into normal range (14-74 pg/mL) at 10 minutes after excision of the parathyroid adenoma is indicative of removal of all hyperfunctioning parathyroid tissue. Successful parathyroidectomy is defined as normocalcemia at six months post-operatively. Using the IOPTH assay, minimally invasive parathyroidectomy has achieved cure rates of >95

percent, consistent with the long-term success rate of a traditional four-gland exploration.

The increasing incidence of asymptomatic patients with primary hyperparathyroidism makes the decision to proceed with parathyroidectomy challenging for patients and their healthcare providers. At Froedtert & The Medical College, all patients are evaluated for surgery and for MIP when possible by an interdisciplinary team of endocrinologists, radiologists and surgeons. Patients with primary hyperparathyroidism may be referred to the Froedtert & The Medical College by calling our referral specialist Gail Laschen at 414-805-6849.

References

1. Bilezikian JP, Khan AA, Potts JT. Guidelines for the management of asymptomatic primary hyperparathyroidism: Summary statement from the third international workshop. *J Clin Endocrinol Metab* 2009; 94: 335-339.

2. Udelsman R. Six hundred fifty-six consecutive explorations for primary hyperparathyroidism. *Ann Surg* 2002; 235: 665-670.
3. DeLellis RA, Mazzaglia P, Mangray S. Primary hyperparathyroidism: A current perspective. *Arch Pathol LabMed* 2008; 132: 1251-1262.
4. Rodgers SE, Hunter GH, Hamberg LM, et al. Improved preoperative planning for directed parathyroidectomy with 4-dimensional computed tomography. *Surgery* 2006;140:932-940.
5. Mortenson MM, Evans DB, Lee JE, et al. Parathyroid exploration in the reoperative neck: improved preoperative localization with 4D-computed tomography. *J Am Coll Surg* 2008;206:888-895.

UPDATE FROM THE CLINICAL RESEARCH CORE

By Anne Laulederkind, BSN, CCRC
and Laura Burgardt, CMA

Clinical Research Coordinators

Pancreatic Tissue Bank for Dedicated Translational Research in the Study of Human Pancreatic Cancer; Principal Investigator: Douglas B. Evans, MD, Chairman, Department of Surgery

Hepatobiliary and pancreatic surgeons at the Froedtert & The Medical College of Wisconsin Clinical Cancer Center are developing a tissue repository for pancreatic cancer. A small portion of tumors removed at the time of surgery will be submitted to the tumor bank. The ability to use human tumors for research is critically important to advancing our understanding of the biology of this disease. Pancreatic cancer is currently the fourth leading cause of adult cancer death, and improved techniques for early diagnosis and treatment are desperately needed. If the “left-over” tumor tissue is not preserved in a dedicated tumor bank, it would be stored in pathology for a period of time. Unless frozen immediately, the DNA and RNA are often unable to be used in a meaningful way. Working with such a tissue bank, Medical College of Wisconsin researchers will have the ability to translate basic discoveries in the laboratory to the reality of patient care.

A Randomized Phase II Study of Preoperative Chemotherapy (Gemcitabine and Erlotinib) with or without Radiation

Therapy for Patients with Resectable Adenocarcinoma of the Pancreas; Principal Investigator: Kathleen K. Christians, MD, Associate Professor of Surgery

This two-center study initiated by The University of Texas M.D. Anderson Cancer Center is designed for patients who have been diagnosed with Stage I or II pancreatic cancer and are previously untreated. Up to 190 patients will take part in the study at both locations; we hope to include 48 patients at Froedtert & The Medical College of Wisconsin. Patients will be treated with chemotherapy (Gemcitabine and Erlotinib) before and after surgery, with or without radiation therapy. At present, the use of radiation therapy in patients with Stage I and II pancreatic cancer is controversial. In the United States, radiation therapy is commonly used, whereas in Europe it is felt to be unnecessary. In this trial, those patients who are randomized to receive chemotherapy alone may receive radiation therapy at the end of all treatment if a surgical margin is positive. The goal of this study is to assess the effect of chemotherapy with or without radiation therapy on the surgically excised tumor (which is studied under the microscope in detail). For more information on this clinical trial, please refer to the publication list developed by Douglas Evans, MD, by visiting froedtert.com/evans.


A Phase II Study of Preoperative Gemcitabine and Erlotinib Plus Pancreatectomy and Postoperative Gemcitabine and Erlotinib for Patients with Operable Pancreatic Adenocarcinoma

Principal Investigator: Sam G. Pappas, MD, Assistant Professor of Surgery

This study, developed by the American College of Surgeons Oncology Group (ACOSOG Z5041) is designed as a large multi-institutional study to provide further data on the optimal treatment sequencing of surgery and chemotherapy in patients with localized Stage I and II pancreatic cancer. Emerging data from a number of institutions have suggested that chemotherapy prior to surgery may be superior to a “surgery first” treatment strategy; yet, this approach remains somewhat controversial. Patients at the Froedtert & The Medical College of Wisconsin Clinical Cancer Center who participate in this study will receive chemotherapy consisting of Gemcitabine plus Erlotinib before and after surgery. This trial will provide important data on the entire care pathway of patients with localized pancreatic cancer, including the accuracy of pre-treatment imaging, the technical aspects of surgery, and recurrence rates and patterns of failure for patients treated with this program. Trial results across all institutions will also have implications for whether or not radiation therapy should be considered in future trials. The chemotherapy drugs used in this study (Gemcitabine and Erlotinib) are FDA approved and commercially available, but their use together in patients with early stage pancreatic cancer is new.

Upcoming Clinical Trials

Look for information on hepatopancreaticobiliary, general surgery and surgical oncology clinical trials in the next issue of *Surgery Update*.

 CUT ALONG LINE TO DETACH

The Department of Surgery, Medical College of Wisconsin thanks you for your gift!

The Department of Surgery welcomes support for research and education. All donations are used in support of the academic achievement of our residents and faculty.

Please direct my (our) gift to the following area(s):

- | | |
|--|--|
| <input type="checkbox"/> Purposes of Stuart D. Wilson Chair, Division of Surgical Oncology | <input type="checkbox"/> Resident Training and Education (Future Surgical Skills Center) |
| <input type="checkbox"/> C. Morrison Schroeder Endowed Lectureship | <input type="checkbox"/> Carl W. Eberbach Endowed Lectureship |
| <input type="checkbox"/> Other (please specify) _____ | |

My (our) gift of \$ _____

- Enclosed is a check made payable to the Medical College of Wisconsin
- Credit Card Payment (please circle) Visa MC American Express Discover

Credit Card # _____ Exp. Date ____/____/____

Authorized Signature: _____

Please mail donations to:
Medical College of Wisconsin
Department of Surgery
Attn: Tracy Milkowski
9200 W. Wisconsin Ave.
Milwaukee, WI 53226

Thank you! Gifts to the Department of Surgery, Medical College of Wisconsin are tax-deductible as allowed by law.

CLINICAL TRIALS

Each issue of Surgery Update will highlight current clinical trials. Be sure to look inside for more details, and call us with inquiries about clinical trials that may fit your patients' needs. Thank you for considering Froedtert & The Medical College of Wisconsin.

PANCREATIC CANCER

Tissue Bank

Principal Investigator:
Douglas B. Evans, MD

Hepatobiliary and pancreatic surgeons at the Froedtert & The Medical College of Wisconsin Clinical Cancer Center are developing a tissue repository for pancreatic cancer. A small portion of tumors removed at the time of surgery will be submitted to the tumor bank.

Preoperative and Postoperative Chemotherapy with or without Radiation Therapy

Principal Investigator:
Kathleen K. Christians, MD

This two-center study initiated by The University of Texas M.D. Anderson Cancer

Center is for patients who have been diagnosed with stage I or II pancreatic cancer and are previously untreated. Patients are treated with chemotherapy (Gemcitabine and Erlotinib) before and after surgery, with or without radiation therapy.

Preoperative and Postoperative Chemotherapy

Principal Investigator: Sam G. Pappas, MD

This study, developed by the American College of Surgeons Oncology Group is a large multi-institutional study designed to provide further data on the optimal sequencing of surgery and chemotherapy in patients with localized Stage I and II pancreatic cancer.

For more information, see page 9.

