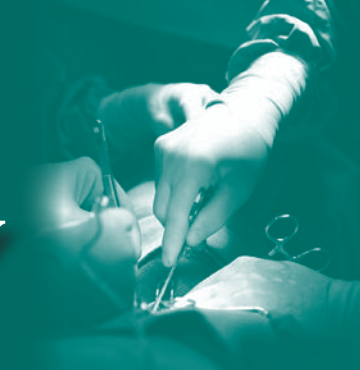

SURGERY UPDATE LEADING THE WAY

FALL 2015 • VOLUME 7, NUMBER 3



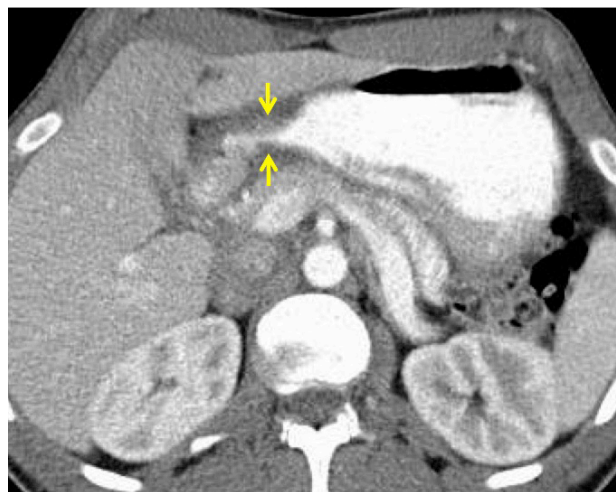
From the Chair

DOUGLAS B. EVANS, MD

Several important points of emphasis which are unrelated to the tremendous content of this issue of *Leading the Way* (thank you to all authors!):

- Our **Annual Reception at the American College of Surgeons** meeting will be held Monday evening, Oct. 5 at the University Club on Monroe Street – easy to get to and we hope to see all of you as the meeting will be in Chicago. Please join us.
- Our **Resident Research Fund** will be formally launched this month to support dedicated research time for our residents. As the financial complexities of medicine have posed added challenges to the support of resident research time, we have started this initiative under the leadership of Dr. Mary Otterson and a committee of prominent surgeons throughout the United States who have “educational ties” to MCW. You will hear more about the Resident Research Fund in the next issue of *Leading the Way*. Importantly, 100% of our current faculty have responded to this campaign.
- The **power of collaboration and direct interdisciplinary care/communication** is something we are reminded of every week.

A young man (early 30s) from the East Coast was referred to us with unexplained weight loss due to early satiety which had been present for a number of months. A small unrelated abnormality (which we feel is benign) in his left kidney caused confusion over the coordination of his diagnostic evaluations and as a result, he experienced what we have termed “paralysis of analysis” — the medical team managing the gastric outlet



Axial image of a contrast-enhanced CT; arrows point to the soft tissue thickness at the duodenum

problem was not directly communicating with the kidney team — he continued to lose weight and there was no direct physician communication and therefore, no plan of care.

He was referred here for a second opinion due to the concern over a duodenal neoplasm. When his referral was received, the combination of a talented referral specialist (Gail Laschen) and an equally talented and experienced NP (Shannon Lahiff) created the glue that the medical system needed: his films were reviewed (pre-referral) by specialists in radiology; the diagnosis of probable inflammatory bowel disease was suggested (also involving the distal ileum); and physicians in Gastroenterology, Pathology and Radiology put the pieces together in three days. He is now receiving anti-TNF therapy and is asymptomatic and gaining weight. Direct communication with a system experienced with rapid and efficient care coordination will often arrive at the correct diagnosis, even when the presentation is confusing and difficult. •

IN THIS ISSUE:

Enhanced Recovery in Complex Hernia Repairs ...	2
Welcome Chief Residents ...	3
Battling Inguinodynia – Chronic Pain Following Inguinal Hernia Repair ...	4
Adhesive Small Bowel Obstruction: Evidence-Based Management Protocol ...	5
Metastatic Thyroid Cancer: Challenges of the Lateral Neck ...	7

Treatment Adjuncts for the Pancreas Cancer Patient: Follow-up Care After Whipple Resection ...	9
New Faculty ...	11
Rethinking Acute Pain Management in the Setting of Rib Fractures ...	12
Pleural Lavage: A Novel Approach to the Prevention of Retained Hemothorax ...	13
Awards and Recognition ...	14

Medical Ethics in the 21st Century ...	15
Medical College of Wisconsin – The University of Texas M. D. Anderson Cancer Center 2015 Endocrine Surgery Symposium ...	16
<i>Get Your Rear In Gear</i> —Visiting Professor ...	18
Faculty Listing ...	19

Enhanced Recovery in Complex



MATTHEW GOLDBLATT, MD
Division of General Surgery

Enhanced Recovery After Surgery (ERAS) is one of the latest trends in General Surgery. It represents a different way of looking at peri-operative protocols to help shorten post-operative ileus, reduce the time for ambulation and ultimately to decrease length of inpatient stays. Two meta-analyses of randomized control trials have shown that implementing ERAS protocols can not only decrease hospital stay, but also decrease peri-operative complications. Much of the literature on this topic has focused around colorectal surgery where “fast-track” protocols have been utilized for years. Some of the techniques for faster recovery include the use of epidurals for post-operative pain, avoidance of bowel preps and peri-operative fluid overload, early removal of urinary catheters, early post-operative feeding and minimizing narcotic pain medications.^{1,2}

At the Condon Hernia Institute, we perform complex abdominal wall reconstruction which historically can have lengths of stay

similar to the colon resections where ERAS pathways were originally designed. Complex abdominal wall reconstruction represents a more comprehensive rebuilding of the abdominal wall for ventral/incisional hernias compared to previous techniques focusing on bridging the hernia defect. These include returning the rectus muscles to the midline using a retro-rectus (Rives-Stoppa) placement of reinforcing material. This technique separates the posterior rectus sheath from the rectus muscle complex and then closes this posterior layer as the first stage of repair. In patients with loss of domain, the transversus abdominis muscle can be cut to medialize the posterior sheath in a technique called the transversus abdominis release (TAR). The TAR creates a reduction in tension on the posterior sheath without sacrificing the neurovascular supply to the abdominal wall. Then the second layer of closure is performed by placing a prosthetic material reinforcement within the retro-rectus space and securing it to the anterior rectus sheath laterally. Closing the anterior rectus sheath completes the repair with the third and final strength layer. This repair has multiple advantages over a standard bridging mesh. First, there are three layers of midline closure (two layers of fascia and one layer of a prosthetic material). Second, the rectus muscles are returned to midline, thereby returning core muscle strength. Finally, the reinforcing material is able to be kept out of the peritoneal cavity, minimizing the risk of bowel/mesh interactions.

The Rives-Stoppa repair is typically an open procedure lasting two to four hours. Post-operative pain can be significant and hospital lengths of stay typically range from five to seven days. The post-operative ileus is the main reason for the prolonged hospital course. Most herniologists feel that a Rives-Stoppa repair is one of the best ways to definitively reconstruct the abdominal

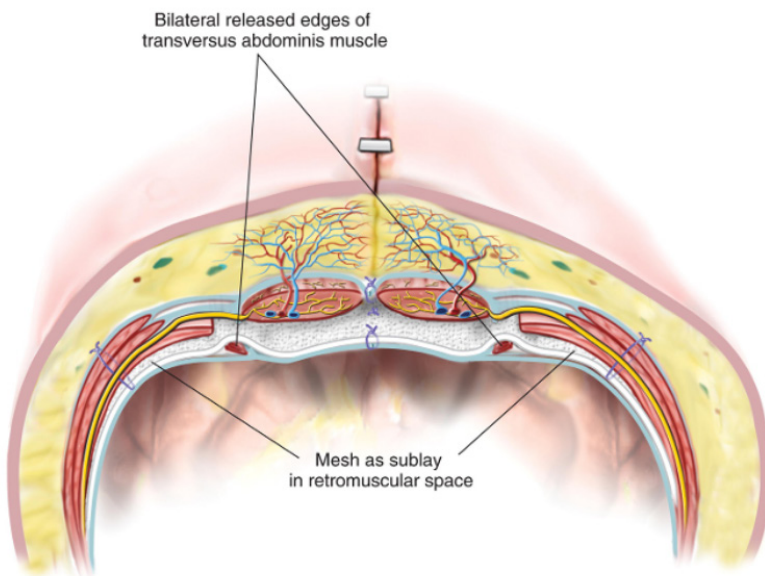


FIGURE 1: The mesh is placed as a sublay in the retromuscular space.

Image used with permission, *Atlas of Abdominal Wall Reconstruction*, copyright 2012 Saunders, Elsevier Inc.

Hernia Repairs

wall. Unfortunately, the excellent outcomes from this complex repair come with a long hospital course; and therefore, there is an excellent opportunity for some of the ERAS techniques.

Alvimopan (Entereg, Merck) is a mu opioid receptor blocker that does not cross the blood-brain barrier. Essentially, it inhibits the effects of opioids on the bowel, without blocking the pain relieving effects on the spinal cord and brain. By decreasing the effects of narcotics on the bowel, Alvimopan has been shown to accelerate the return of bowel function in colo-rectal patients by up to two days.³ Alvimopan is only FDA approved in patients undergoing a bowel resection, and so its use in complex abdominal wall reconstruction has not been clinically tested. At the Condon Hernia Institute, we have initiated a double-blinded prospective randomized trial comparing Alvimopan with placebo in complex hernia patients. The risk profile of this approved prescription medication is minimal and many of our patients will be offered to join the study before embarking on their complex abdominal wall reconstruction. Enrollment for this study is expected to begin shortly to determine if the same decrease in hospital stay seen in colo-rectal procedures can be replicated in hernia cases. •

FOR ADDITIONAL INFORMATION on this topic, see references below, visit mcw.edu/surgery, or contact Dr. Goldblatt at mgoldbla@mcw.edu, 414-805-5714.

REFERENCES

1. Adamina M, *et al*, Enhanced recovery pathways optimize health outcomes and resource utilization: a meta-analysis of randomized controlled trials in colorectal surgery. *Surgery*, 2011;149:830-840.
2. Varadhan KK, *et al*; The enhanced recovery after surgery (ERAS) pathway for patients undergoing major elective open colorectal surgery: a meta-analysis of randomized controlled trials. *Clin Nutr*, 2010;29:434-440).
3. Ludwig K, *et al*, Gastrointestinal Tract Recovery in Patients Undergoing Bowel Resection. *Arch Surg*, 143:1098-1105.

DEPARTMENT OF SURGERY CHIEF RESIDENTS 2015–2016



Ahmed Ali, MD



Betsy Appel, MD



Ryan Berg, MD



Nathan Heinzerling, MD



Kevin Hudak, MD




Abby Rothstein, MD



Kathleen Simon, MD

Battling Inguinodynia – Chronic Pain Following Inguinal Hernia Repair



ANDREW KASTENMEIER, MD
Division of General Surgery

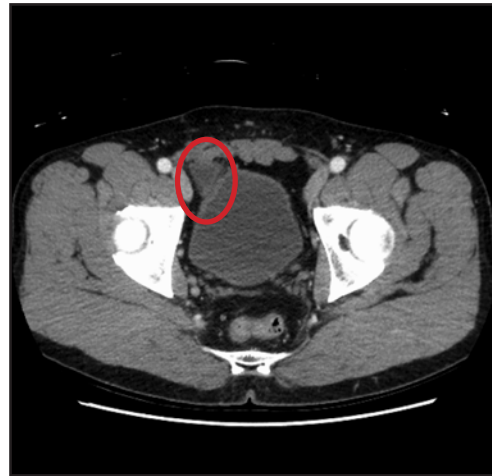There are few surgical diseases as common as the inguinal hernia. With approximately 20 million inguinal hernia repair operations conducted worldwide on an annual basis, it has remained one of the most commonly performed surgical procedures in existence. The incidence of inguinal hernias in men is staggering with nearly 1 in 4 suffering from the disease during their lifetime. The vast majority of those who undergo an inguinal hernia repair achieve resolution of their hernia symptoms and dramatic improvement in quality of life. However, with such large numbers of people undergoing surgical repair, even an infrequent long-term complication will be of significance. Such is the case for *inguinodynia*.

Inguinodynia is chronic groin pain that persists greater than 3–6 months following inguinal hernia repair. The true rate is difficult to determine, but inguinodynia now outpaces hernia recurrence as the most frequent long-term complication after inguinal hernia repair. There has been great improvement in the durability of inguinal hernia repairs in recent years with the use of mesh and tension-free repair techniques. Subsequently, hernia recurrence rates have fallen quite dramatically. In fact, inguinal hernia repair durability has resulted in such low recurrence rates that inguinodynia has surpassed hernia recurrence as the most common, the most feared, and the most difficult to treat long-term complication after inguinal hernia repair.

Anyone who has encountered a patient suffering from inguinodynia can attest to the dramatic impact this condition has on quality of life. Inguinodynia is potentially disabling and can limit physical activity, limit social activity, cause psychological distress, destroy sleep quality, and impact work productivity.

The cause of inguinodynia is both variable and multifactorial. This makes inguinodynia a difficult and often frustrating condition to treat. Potential causes include hernia recurrence, neuropathic pain due to nerve entrapment, meshoma, orchalgia, periostitis pubis, funiculocynia (spermatic cord pain), and musculoskeletal pain. Some of these issues are best addressed surgically, but many are managed non-operatively.

At the Medical College of Wisconsin Condon Hernia Institute, we have a multidisciplinary approach to the diagnosis and treatment of inguinodynia. We work closely with pain management specialists, physical therapists, sports medicine specialists and radiologists to identify the cause(s) of inguinodynia and the optimal targeted



This axial-view CT scan image shows a mesh plug that was used to repair a inguinal hernia. Mesh plugs can be one of many possible sources of inguinodynia following inguinal hernia repair.

treatments. Additionally, patient cases are often reviewed at the MCW multidisciplinary hernia conference where physicians convene to discuss the diagnostic and management strategies for difficult cases. Treatment strategies may include any combination of the following: pharmacologic therapy, physical therapy, interventional pain management, and/or surgical pain management. Surgical options include the laparoscopic approach to recurrent hernia repair, neurectomy, mesh excision, and/or foreign body removal. These procedures are often offered in combination with other pain management modalities. At the Medical College of Wisconsin Condon Hernia Institute, we offer patients a thoughtful, stepwise approach to inguinodynia. Our goal is to help patients suffering from inguinodynia to minimize symptoms and maximize quality of life. •

FOR ADDITIONAL INFORMATION on this topic, see references below, visit mcw.edu/surgery, or contact Dr. Kastenmeier at akastenm@mcw.edu, 414-805-5714.

REFERENCES

- Bjurstrom MF, Nicol AL, Amid PK, Chen DC. Pain control following inguinal herniorrhaphy: current perspectives. *J Pain Res*, 2014 May 29;7:277-90.
- Loos MJ, Roumen RM, Scheltinga MR. Classifying post-herniorrhaphy pain syndromes following elective inguinal hernia repair. *World J Surg*, 2007 Sep;31(9):1760-5; discussion 1766-7.

Adhesive Small Bowel Obstruction: Evidence-Based Management Protocol



COLLEEN TREVINO, MSN, PHD
Division of Trauma/CC/ACS



TRAVIS WEBB, MD, MHPE
Division of Trauma/CC/ACS

The codification of the Acute Care Surgery model has led to increased interest in standardizing the management and improving outcomes of conditions commonly seen by the emergency general surgery team. Small bowel obstruction (SBO) is one of those common conditions leading to surgical consultation and admission to US hospitals, accounting for 15% of acute surgical admissions.¹ In the US, there are over 300,000 hospitalizations for SBO and another 300,000 operations performed for SBO adhesiolysis per year in adults.² These hospitalization and operation rates have remained steady over the past 20 years. Furthermore, SBO accounts for more than \$2.3 billion in healthcare expenditures.³ Standardizing the care for this large population holds promise to ensure best practices, efficient care, and reduce hospital costs.

The most common etiologies for SBO in Western society today are adhesions, malignancy, hernia, and Crohn's disease.⁴⁻⁷ Peritoneal adhesions account for 50% to 80% of all bowel obstructions.⁸ Strategies for the management of small bowel obstructions (SBOs) have changed significantly over the years. The old adage "never let the sun set or rise on a bowel obstruction" has been replaced with individualized care of the patient with obstructive symptoms. Non-operative medical management has become the mainstay of treatment for most small bowel obstructions. However, there are situations where surgery is indicated. These situations must be identified early and swiftly in order to prevent bowel ischemia and necrosis, which result in increased morbidity and mortality.

Standardization of SBO management by an Acute Care Surgical team can improve adherence to evidence-based guidelines by decreasing variation in care and allowing for quality assurance. Guidelines for the management of SBO have been recently published which provide a foundation for early identification of patients unlikely to resolve with medical therapy. Both the Bologna Guidelines⁹ and the Eastern Association for the Surgery of Trauma guidelines¹⁰ promote the use of water soluble contrast challenge (WSCC) in patients without signs of strangulation or peritonitis, persistent vomiting, or CT signs of bowel ischemia. They have recommended the administration of contrast anywhere between the time of admission to 48 hours after initiation of medical management. There is good evidence that a WSCC can effectively predict the need for surgery in adhesive SBO and reduce length of hospital stay (LOS). Complete bowel obstructions can be identified and potentially reduce time to operation for those who will

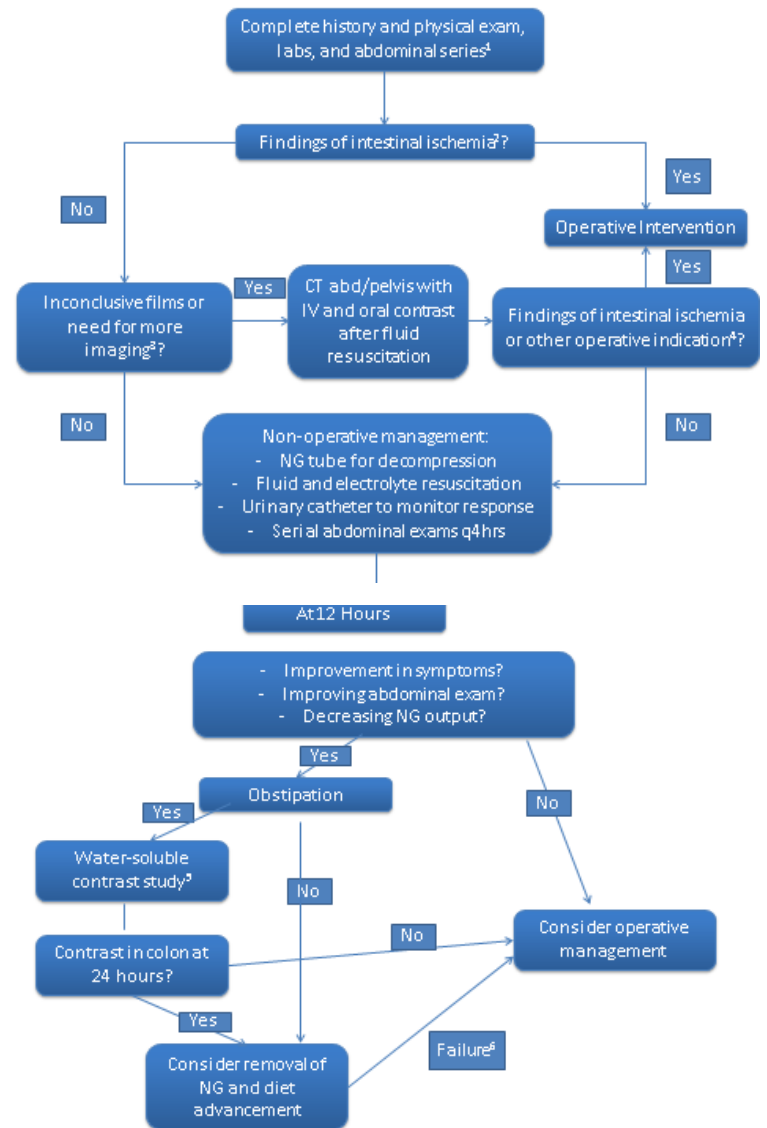

Figure 1: Adhesive SBO Management Protocol

OBSTRUCTION PROTOCOL — CONTINUED FROM PAGE 5

require an operation. It is less conclusive if this intervention can reduce the overall need for surgery. Also, it has not been determined if there is a reduction of small bowel resection and postoperative complications with this reduction in the time to operation. Utilizing our Acute Care Surgery practice model, we felt that designing and implementing guidelines for the identification and management of adhesive SBO would improve standardization of practice and our patient's outcomes.

Our protocol (Figure 1) was developed utilizing the current practice guidelines, specifically incorporating a WSSC. The protocol provides a management algorithm based upon clinical and diagnostic criteria. The first step is diagnosis based upon a history, physical exam, laboratory values and an abdominal series. Findings suggestive of intestinal ischemia and absolute indications for operative management include peritonitis on exam, free intraperitoneal air on plain films, and/or irreducible hernia. Relative indications that are concerning though less specific include elevated lactate, fever, tachycardia, severe pain, focal tenderness, and leukocytosis > 15,000. Indications for CT scan include patients who meet some relative indications but are not felt to necessitate urgent operative intervention, those with no history of abdominal surgery nor any hernias noted on exam, and those in which the diagnosis of small bowel obstruction is in doubt. If it is determined there is no evidence of ischemia, nonoperative management with a nasogastric tube, fluid and electrolyte resuscitation, urine output monitoring and serial abdominal exams are implemented. At 12 hours post-admission, if there is improvement in abdominal symptoms, the abdominal exam, and/or decreasing nasogastric output, yet obstipation continues, a WSSC is performed. The WSSC study is ordered as a bolus of 50 ml of Omnipaque orally or down the nasogastric tube (NGT) with clamping of the NGT for 6 hours. A KUB is obtained at 6 hours after contrast administration. Failure of nonoperative management is defined by: persistent abdominal pain and/or distension, nasogastric drainage volume >500cc/24hrs on hospital day #3, fever at 48–72 hours, white blood cell count (WBC) > 10,000, any findings of intestinal ischemia, or no evidence of contrast in the colon by 24 hours after administration. In the case of failure of nonoperative management, operative management is considered. Utilization of this protocol has improved our usage of evidence-based guidelines and standardized care to improve efficiency of our service. The development of an emergency general surgery service was instrumental in promoting this type of coordinated care planning and will continue to provide a focus on emergency general surgery disease processes and outcomes. •

FOR ADDITIONAL INFORMATION on this topic, see references below, visit mcw.edu/surgery, or contact Dr. Webb at trwebb@mcw.edu, or 414-805-8622.

REFERENCES

1. Miller G, Boman J, Shrier I, Gordon Ph. Etiology of small bowel obstruction. *Am J Surg*, Jul 2000;180(1):33-36.
2. Scott FI, Osterman MT, Mahmoud NN, Lewis JD. Secular trends in small bowel obstruction and adhesiolysis in the United States, 1988-2007. *Am J Surg*, 2012;204:315-320.
3. Sikirica V, Bapat B, Candrilli SD, *et al.* The inpatient burden of abdominal and gynecological adhesiolysis in the US. *BMC Surg*, 2011;11-13.
4. Foster NM, McGory ML, Zingmond DS, Ko CY. Small bowel obstruction: a population-based appraisal. *J Am Coll Surg*, 2006;203:170-176.
5. Menzies D, Parker M, Hoare R, Knight A. Small bowel obstruction due to postoperative adhesions: treatment patterns and associated costs in 110 hospital admissions. *Ann R Coll Surg Eng*, 2001;83:40-46.
6. Ray NF, Denton WG, Thamer M, *et al.* Abdominal adhesiolysis: inpatient care and expenditures in the United States in 1994. *J Am Coll Surg*, 1998;186:1-9.
7. Mucha P Jr. Small intestinal obstruction. *Surg Clin North Am*, 1987;67:597-620
8. Hayanga AJ, Bass-Wilkins K, Bulkley GB. Current management of small-bowel obstruction. *Adv Surg*, 2005;39:1-33.
9. Di Saverio S, Coccolini F, Galati M, *et al.* Bologna guidelines for diagnosis and management of adhesive small bowel obstruction (ASBO): 2013 update of the evidence-based guidelines from the World Society of Emergency Surgery ASBO working group. *World J Emerg Surg*, 2013;8:42
10. Maung AA, Johnson DC, Piper GL, Barbosa RR, *et al.* Evaluation and management of small-bowel obstruction: An Eastern Association for the Surgery of trauma practice management guideline. *J Trauma Acute Care Surg*, 2012;73:S362-S369.

Metastatic Thyroid Cancer: Challenges of the Lateral Neck



JASON A. GLENN, MD
General Surgery Resident



TRACY S. WANG, MD, MPH
Division of Surgical Oncology

With 62,000 new cases expected to occur in the United States in 2015, thyroid cancer is the most common malignancy of the endocrine system. Papillary thyroid carcinoma, which accounts for >90% of thyroid cancers, frequently metastasizes to cervical lymph nodes early in its course. When a multidisciplinary treatment approach is employed, the prognosis of thyroid cancer remains excellent (98% 5-year survival for patients with cervical lymph node metastases); however, locoregional recurrences have been reported following >10% of neck dissections.^{1,2} Reoperation for locoregional recurrence has been associated with higher rates of endocrine-specific morbidity (e.g. hypoparathyroidism and recurrent laryngeal nerve injury); therefore, a comprehensive preoperative evaluation and consideration of the extent of surgery are essential to limit operative morbidity and minimize the risk of locoregional recurrence.²

Current American Thyroid Association (ATA) guidelines recommend a therapeutic lateral neck dissection (LND) for patients with clinical or radiographic evidence of lateral neck metastases; there is no role for prophylactic LND.³ Traditional ‘radical’ neck dissections, in which non-lymphatic structures (i.e. spinal accessory nerve, internal jugular vein, and sternocleidomastoid muscle) were routinely resected, have been shown to be associated with significant morbidity, without improving disease-free survival. In contrast, a selective, compartment-oriented LND (levels IIa, III, IV, and Vb; Figure 1) lowers operative morbidity by preserving non-lymphatic structures, and also avoids the dissection of lymph nodes that have a low likelihood of metastases, such as those in levels I, IIb, and Va.³

When performing a LND, comprehensive knowledge of the anatomy of the lateral neck is essential in order to minimize operative morbidity.^{4,5} The dissection of levels IV and V at the level of the thoracic inlet can predispose the thoracic duct to injury, as the anatomy of the lymphatic system is highly variable in this location (Figure 2); injury to the main thoracic duct or any of its branches can result in a chyle leak if not recognized and repaired

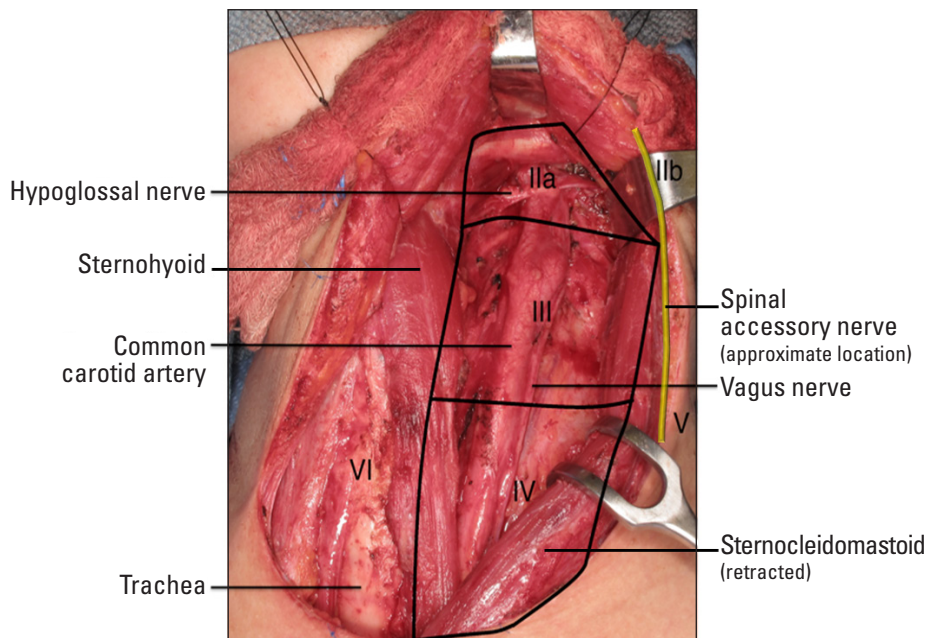


Figure 1: Intraoperative photo of the left lateral neck – Selective compartment-oriented lateral neck dissection of levels IIa, III, and IV.

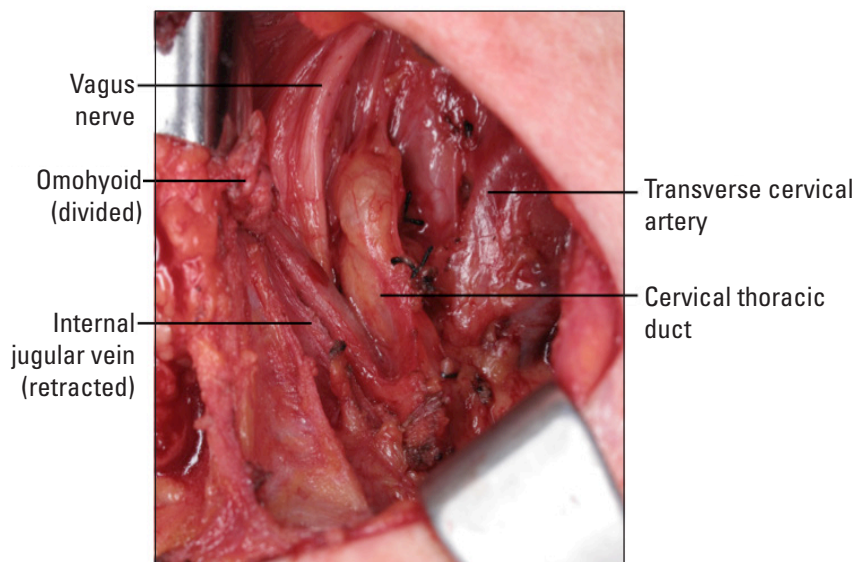


Figure 2: Intraoperative photo of the left lateral neck – Cervical thoracic duct.

at the time of initial operation.^{6,7} Spinal accessory nerve injury is often cited as the most common complication following LND; some studies report that up to 50% of people experience some degree of neuropraxia (shoulder weakness/pain) following LND.^{8,9} Variations in nerve branching, intercalation with the cervical plexus, and intraoperative misidentification of the spinal accessory nerve as the minor occipital nerve likely contribute to increased rates of injury when LND is performed by less experienced surgeons.^{10,11}

Results

From 2009 to 2014, thyroid surgery specialists at MCW performed more than 1,100 thyroid-related operations.¹² Of the 414 patients treated for thyroid cancer during this time, 96 (23%) had suspicion of lateral neck metastases and subsequently underwent selective LND. Overall, 14 patients experienced 20 complications, including seven chyle leaks, twelve wound-related complications, and one persistent spinal accessory nerve injury. Of the patients with a chyle leak, five were successfully managed with diet modification in an outpatient setting; the remaining two patients required reoperation for persistently high drain outputs. Most surgical site infections and/or seromas were managed conservatively with antibiotics and symptomatic support; however, three patients required percutaneous drainage for refractory fluid collections. Six patients had temporary spinal accessory neuropraxias that resolved with short-term physical therapy. Only one patient had persistent shoulder weakness, suggesting a spinal accessory nerve injury after reoperative LND.¹²

Comment

Previous studies have reported that high-volume thyroid surgeons are up to 73% more likely to perform neck dissections, yet they are half as likely to experience procedure-related complications.^{13,14} The results of this study suggest that routine drain placement during LND may aid in the early identification of chyle leak and the prevention of significant seroma formation, without significantly increasing the risk of infection. Similarly, surgeon experience and the routine initiation of physical therapy within the first postoperative week likely minimize the potential morbidity of cervical nerve injuries. While early postoperative complications were relatively common (~14% in this cohort), they were typically amenable to conservative management; only one patient with a spinal accessory nerve injury experienced a long-term complication following LND. Most patients in this study were discharged following a standard 23-hour admission and the majority of complications were identified and treated in the outpatient setting. These findings highlight the importance of multidisciplinary care, patient education, an experienced high-volume surgical team, and continuity of care between the inpatient and outpatient settings in the management of thyroid cancer. •

FOR ADDITIONAL INFORMATION on this topic, see references, visit mcw.edu/surgery, or contact Dr. Wang at tswang@mcw.edu, or 414-805-5755.

REFERENCES

1. SEER Cancer Statistics Factsheets: Thyroid Cancer. National Cancer Institute. Bethesda, MD: <http://seer.cancer.gov/staffacts/html/thyro.html>; 2013.
2. Conzo G, Docimo G, Mauriello C, Gambardella C, Esposito D, Cavallo F, *et al*. The current status of lymph node dissection in the treatment of papillary thyroid cancer. A literature review. *La Clinica Terapeutica*, 2013;164(4):e343-6.
3. Cooper DS, Doherty G, Haugen B, Kloos R, Lee S, Mandel S, *et al*. Revised American Thyroid Association Management Guidelines for Patients with Thyroid Nodules and Differentiated Thyroid Cancer. *Thyroid*, 2009;19(11).
4. Kupferman ME, Patterson DM, Mandel SJ, LiVolsi V, Weber RS. Safety of modified radical neck dissection for differentiated thyroid carcinoma. *The Laryngoscope*, 2004;114(3):403-6.
5. Welch K, McHenry CR. Selective lateral compartment neck dissection for thyroid cancer. *The Journal of Surgical Research*, 2013;184(1):193-9.
6. Ammar K, Tubbs RS, Smyth MD, Wellons JC, 3rd, Blount JP, Salter G, *et al*. Anatomic landmarks for the cervical portion of the thoracic duct. *Neurosurgery*, 2003;53(6):1385-7; discussion 7-8.
7. Brennan PA, Blythe JN, Herd MK, Habib A, Anand R. The contemporary management of chyle leak following cervical thoracic duct damage. *The British Journal of Oral & Maxillofacial Surgery*, 2012;50(3):197-201.
8. Carr SD, Bowyer D, Cox G. Upper limb dysfunction following selective neck dissection: a retrospective questionnaire study. *Head & Neck*, 2009;31(6):789-92.
9. Cheng PT, Hao SP, Lin YH, Yeh AR. Objective comparison of shoulder dysfunction after three neck dissection techniques. *The Annals of Otolaryngology, Rhinology, and Laryngology*, 2000;109(8 Pt 1):761-6.
10. Kierner AC, Zelenka I, Heller S, Burian M. Surgical anatomy of the spinal accessory nerve and the trapezius branches of the cervical plexus. *Arch Surg*, 2000;135(12):1428-31.
11. Lanisnik B, Zargi M, Rodi Z. Identification of three anatomical patterns of the spinal accessory nerve in the neck by neurophysiological mapping. *Radiology and Oncology*, 2014;48(4):387-92.
12. Glenn JA, Yen TW, Fareau GG, Carr AA, Evans DB, Wang TS. Institutional Experience with Lateral Neck Dissections for Thyroid Cancer. *Surgery*, 2015; [epub ahead of print].
13. Gourin CG, Tufano RP, Forastiere AA, Koch WM, Pawlik TM, Bristow RE. Volume-based trends in thyroid surgery. *Archives of Otolaryngology—Head & Neck Surgery*, 2010;136(12):1191-8.
14. Loyo M, Tufano RP, Gourin CG. National trends in thyroid surgery and the effect of volume on short-term outcomes. *The Laryngoscope*, 2013;123(8):2056-63.

Treatment Adjuncts for the Pancreas Cancer Patient: Follow-up Care After Whipple Resection



JOSEPH ZECHLINSKI, MD
Vascular Interventional Radiology Fellow



BETSY APPEL, MD
Chief Resident in Surgery



MINA MIRHOSEINI
Senior Medical Student

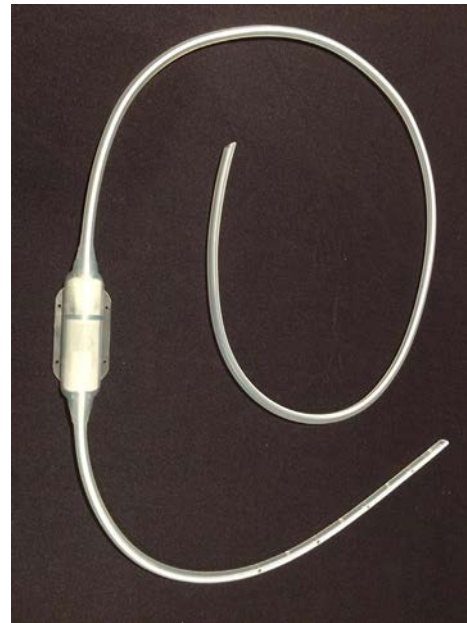


FIGURE 1:
Denver® shunt showing peritoneal and venous limbs with intervening one-way valve (CareFusion, Waukegan, IL).

Recently, a 63 year-old woman with a history of a gastric bypass was referred to our institution after undergoing a Whipple procedure for a poorly differentiated adenocarcinoma of the pancreas eight months prior to our consultation. A surgery-first approach was utilized. At the time of surgery, there was invasion of the superior mesenteric vein (SMV), and this was managed with a bovine pericardial patch reconstruction. Following an initial satisfactory recovery, early post-operative surveillance scans detected thrombus within the reconstructed SMV. This progressed to SMV occlusion despite oral anticoagulation. What was unique in this case was that her inferior mesenteric vein (IMV) drained into the SMV, rather than the splenic vein as is more commonly the case. Thus, upon occlusion of her SMV, all venous drainage from her mid-gut was compromised. She developed severe non-malignant ascites, refractory to diuretics, requiring paracenteses every other week of up to 8-10 liters at a time. Her performance status gradually declined, and she sought a second opinion at the Medical College of Wisconsin.

Despite receiving adjuvant gemcitabine, at the time of referral she had what appeared to be a local-regional recurrence at the hepaticojejunostomy. This resulted in upstream biliary dilation and mild hyperbilirubinemia. Endoscopic retrograde cholangiopancreatography (ERCP) was attempted, but because of her prior gastric bypass, her biliary anastomosis could not be reached to allow for placement of a stent.

This patient presented to us with two unrelated issues: non-malignant, refractory ascites secondary to SMV occlusion (a technical complication related to surgery) and impending biliary obstruction secondary to stricture within the afferent (pancreaticobiliary) limb due to tumor recurrence. Her ascites increased her fatigue and lowered her functional

status. Her local recurrence would require further systemic therapy, which could not be administered until her ascites and hyperbilirubinemia were addressed.

Pancreatic cancer patients can endure complications throughout their treatment course, both pre and post surgery. When this happens, the question arises – with all of this complexity, who is responsible for managing the complications and keeping the patient on course with therapy? Is it the surgeon, the medical oncologist, the radiation oncologist, the interventional radiologist? With a team approach in place, these obstacles are tackled more efficiently. In this case, after careful review, a plan was formulated with coordination from surgical oncology and interventional radiology to address both of these disease-related complications.

Initially, the patient underwent placement of a peritoneovenous (PV) shunt for refractory ascites, a technique first described by LeVeen *et al* in 1974, which redirects ascitic fluid into the systemic venous circulation. Now available as a Denver® shunt (CareFusion, Waukegan, IL; Figure 1), the device consists of a soft catheter with a fenestrated peritoneal limb inserted into the abdominal cavity and connected to a venous limb draining into the superior vena cava, via the internal jugular or subclavian vein. As pressure within the peritoneum increases, the fluid is shunted from the peritoneal space via an intervening one-way valve into the central venous system, ensuring unidirectional flow of ascites. The valve is housed in a pump that can also be primed to prevent shunt occlusion. The procedure is minimally invasive beginning with a small incision at the right inferior costal margin for placement of the pump apparatus within a subcutaneous pocket, followed by subcutaneous tunneling of the peritoneal and venous limbs.

WHIPPLE RESECTION — CONTINUED ON PAGE 10 >>

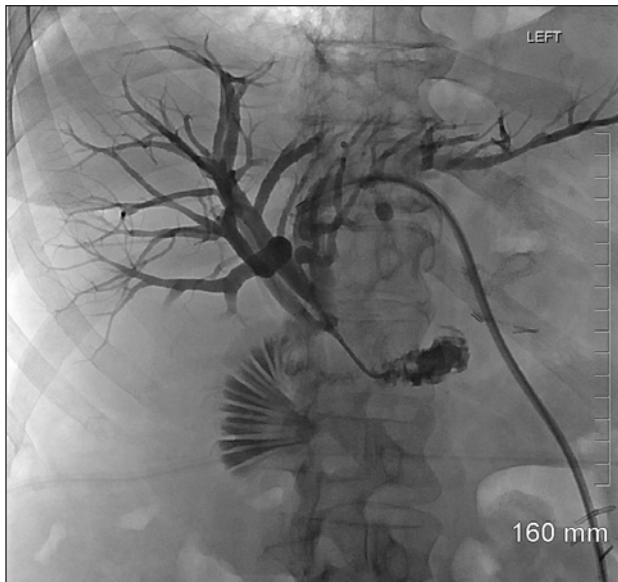


FIGURE 2: Percutaneous transhepatic catheter accessing the biliary system, with contrast filling the biliary tree and afferent limb.

Central venous access is obtained under ultrasound guidance, similar to the technique employed for any device which requires central venous access.

Peritoneovenous shunts allow the diversion of malignant and nonmalignant ascites into the bloodstream, which mitigates complications of frequent large volume paracentesis such as hypoalbuminemia, salt wasting, and malnutrition. The physical benefits of reducing abdominal girth include improved mobility and respiratory status. Physiologic benefits are significant and include improving renal function by restoring the plasma volume normally lost to ascites, improving renal blood flow and diminishing the hyper-aldostronomic state in which most patients with severe ascites live.

Post-operative care and monitoring of PV shunts is minimal. However, complications include shunt occlusion and leakage of ascitic fluid. The patient is required to prime the shunt 20 times twice daily to prevent proteinacious build-up in the system. Immediately post-operatively, the patient should also be monitored for any signs of coagulopathy, as this has been associated with PV shunts, owing to the presence of fibrinolytic products within ascitic fluid. This is generally avoided by performing a paracentesis at the time of shunt placement with reinfusion of saline, in order to adequately prime the system and also avoid air embolism.

With a Denver® shunt now in place, the second issue of impending biliary obstruction was addressed. Because of her post-Whipple anatomy and the length of the patient's afferent limb, an endoscopic approach was felt to be impossible. Instead, percutaneous transhepatic access was gained into the dilated biliary system – a procedure also first reported in 1974 following the introduction of the thin-walled Chiba needle,

which allows relatively safe traversal of the liver parenchyma for placement of an internal/external percutaneous biliary drain (Figure 2). With the external portion of the tube capped to limit fluid/salt losses (which can be significant with biliary drainage), the internal pigtail portion of the tube was placed within the afferent jejunal limb. Initially, the patient developed signs of cholangitis during the cap trial, as well as ongoing hyperbilirubinemia. Careful review of prior imaging suggested the presence of several strictures involving the afferent limb. Therefore, a drainage catheter was prepared with sufficient length to place the internal pigtail well downstream of all strictured bowel segments. Following this manipulation, the patient's symptoms and her hyperbilirubinemia resolved.

Complications of percutaneous biliary drainage include post-procedure sepsis, hemorrhage (arising from hepatic artery-to-portal vein fistula, pseudoaneurysm, or venous bleeding), and bile leakage. Occasionally, an 'over-the-wire' cholangiogram is performed to evaluate the source of bleeding, which can then be treated with coil embolization or tube upsizing based on the etiology of the problem. Internal/external biliary drains are exchanged every 6-8 weeks, and flushing is performed daily to ensure tube patency.

Both of these procedures demonstrate that with a thoughtful plan and attention to detail, many postoperative complications can be successfully managed using a combination of minimally invasive surgical and interventional radiology techniques. Percutaneous abdominal drainage and celiac plexus block are other examples of techniques which may benefit the pancreas cancer patient depending on the type of postoperative issue at hand. In this case, the patient was able to return home with resolution of her hyperbilirubinemia, a capped biliary drain, and adequate control of her ascites. With satisfactory management of these acute issues, attention could then be redirected to ongoing oncologic concerns and appropriately prepare the patient for potential chemotherapy, radiation, or other emerging novel clinical trials. •

FOR ADDITIONAL INFORMATION on this topic, see references, visit mcw.edu/surgery, contact Dr. Zechlinski at jzechlin@mcw.edu, or Dr. Appel at bappel@mcw.edu.

REFERENCES

- Leveen HH, Christoudias G, Ip M, Luft R, Falk G, Grosberg S. Peritoneovenous shunting for ascites. *Ann Surg*, 1974;180(4):580-591.
- LeVeen HH, Wapnick S, Grosberg S, Kinney MJ. Further experience with peritoneo-venous shunt for ascites. *Ann Surg*, 1976; 184: 574-81.
- Okuda K, Tanikawa K, Emura T, Kuratomi S, Jinnouchi S. Nonsurgical, percutaneous transhepatic cholangiography--diagnostic significance in medical problems of the liver. *Am J Dig Dis*, 1974;19(1):21-36.
- White MA, Agle SC, Padia RK, Zervos EE. Denver peritoneovenous shunts for the management of malignant ascites: A review of the literature in the post LeVeen era. *The American Surgeon*, 2011, 77(8):1070-5.

New Faculty



Christopher Dodgion, MD,
MSPH, MBA

On behalf of John Weigelt, MD, DVM and the Division of Trauma/CC/ACS, we are pleased to welcome Drs. Chris Dodgion and Lucia Chou to the Medical College of Wisconsin and the Department of Surgery faculty.

Christopher Dodgion, MD, MSPH, MBA joins us from Oregon Health and Science University in Portland, Oregon where he recently completed his fellowship in surgical critical care. He earned his medical degree from the University of Utah in 2007. Dr. Dodgion's surgical training was at the University of Wisconsin and this included two years of dedicated research at the Center for Surgery and Public Health Policy at Brigham and Women's Hospital and Harvard Medical School in Boston.

Dr. Dodgion will continue his interest in health services research and outcomes as he begins his faculty position here at MCW.

Lucia Chou, MD also joins us from Oregon Health and Science University in Portland where she recently completed her surgery training. She attended medical school at the University of Illinois. Dr. Chou will work predominantly in the Acute Care Surgery program.



Lucia Chou, MD

On behalf of Dr. Jon Gould and the Division of General Surgery, we are extremely fortunate to have **Tammy Lyn Kindel, MD, PhD** join our faculty. Dr. Kindel joins us from the University of Nebraska Medical Center, where she was on faculty completing her fellowship in minimally invasive and bariatric surgery. Her surgical training was at Northwestern University in Chicago. This included three years of dedicated research at the University of Cincinnati, leading to her Ph.D. in the effects of duodenal-jejunal bypass on glucose homeostasis. Prior to beginning her residency at Northwestern, Dr. Kindel graduated from The Ohio State University College of Medicine. She will continue her interest in the basic science of obesity disorders as well as translational research pertaining to the surgical procedures performed for morbid obesity. She will be involved in the Bariatric and Minimally Invasive Surgical Programs at both Froedtert Hospital and Children's Hospital of Wisconsin. Her husband, Steve Kindel, MD, has joined the Pediatric Cardiology Division as the Director of the Pediatric Heart Failure and Heart Transplant Program at CHW.



Tammy L. Kindel, MD, PhD

Rethinking Acute Pain Management in the Setting of Rib Fractures



NATHAN W. KUGLER, MD
General Surgery Resident



JASMEET S. PAUL, MD
Division of Trauma/CC/ACS



THOMAS W. CARVER, MD
Division of Trauma/CC/ACS

Every year in the United States, more than 3 million individuals are injured with greater than half sustaining thoracic injuries.¹ The majority of thoracic injuries are rib fractures but this seemingly “minor” injury can lead to significant morbidity.^{2,3} Complications including lung consolidation, pneumonia, and empyema are associated with rib fractures, resulting in long inpatient hospital stays and an increased mortality. Prevention of these complications relies on optimal pain control to promote normal respiratory mechanics and effort. While opiate medications have long been the therapeutic backbone, there are serious side effects with these medications that limit their overall effectiveness.^{3,4} Recently, there has been increased emphasis on multimodal pain management using acetaminophen, NSAIDs, and different regional anesthesia techniques to help decrease the amount of narcotics necessary for optimal pain control. While there are benefits to epidurals in rib fracture patients, the invasive nature exposes patients to potential complications and not all patients are candidates for epidural placement. Despite the increasing role of multimodal pain management, we have found that narcotics remain the mainstay for the treatment of rib fracture pain.

There is a growing body of literature on the use of ketamine in the management of acute pain, but no previous studies have investigated the effect of ketamine on rib fracture pain. We feel there is a role for ketamine infusions in this patient population which may result in

improved pain control and decreased narcotic use. The Anesthesia Department at MCW has several protocols in place for the use of ketamine for different patient populations and was interested in partnering with the Division of Trauma/CC/ACS to develop a randomized controlled trial (RCT) designed to determine if there is a benefit of ketamine compared to placebo. The study will recruit a total of 60 rib fracture patients. Patients enrolled in the trial will receive all current standards of care with randomization to receive either a ketamine or placebo infusion. This complex study could only be performed because of the tremendous collaboration among the Division of Trauma/CC/ACS, the Regional Anesthesia and Acute Pain Service, our clinical pharmacists, and the Investigational Drug Service.

We realized that even a small study of only 60 patients required a significant amount of money to cover the costs associated with a RCT. As a new faculty, Dr. Thomas Carver of the Division of Trauma/CC/ACS was eligible for a grant from the Research Affairs Committee and on June 19, 2015, the Research Affairs Committee awarded Dr. Carver a grant in the amount of \$25,000 to cover the entire cost of his study. Dr. Carver is currently deployed with the U.S. Navy, but the study has been launched and the first patients enrolled. •

FOR ADDITIONAL INFORMATION on this topic, see references below, visit mcw.edu/surgery, or contact Dr. Paul at jpaul@mcw.edu, or 414-805-9420 or Dr. Carver at tcarver@mcw.edu, or 414-805-8622.

REFERENCES

1. Manlulu AV, Lee TW, Thung KH, Wong R, Yim AP. Current indications and results of VATS in the evaluation and management of hemodynamically stable thoracic injuries. *European Journal of Cardio-thoracic Surgery: Official Journal of the European Association for Cardio-thoracic Surgery*, 2004;25(6):1048-1053.
2. Sharma OP, Oswanski ME, Jolly S, Lauer SK, Dressel R, Stombaugh HA. Perils of rib fractures. *The American Surgeon*, 2008;74(4):310-314.
3. Flagel BT, Luchette FA, Reed RL, et al. Half-a-dozen ribs: the breakpoint for mortality. *Surgery*, 2005;138(4):717-723; discussion 723-715.
4. Brown SD, Walters MR. Patients with rib fractures: use of incentive spirometry volumes to guide care. *Journal of Trauma Nursing: The Official Journal of the Society of Trauma Nurses*. 2012;19(2):89-91; quiz 92-83.

Pleural Lavage: A Novel Approach to the Prevention of Retained Hemothorax



NATHAN W. KUGLER, MD
General Surgery Resident



JASMEET S. PAUL, MD
Division of Trauma/CC/ACS

Thoracic injuries are present in greater than half of all polytrauma patients and are a notable cause of death in nearly a quarter of these individuals.¹ Thoracic trauma resulting in hemothorax, pneumothorax, or hemothorax can be managed with chest tube placement in the majority of cases. As a busy level one trauma center with over 2,000 admissions annually, management of traumatic hemothorax is a major component of our clinical practice. A hemothorax is drained with a chest tube to allow the lung to expand and restore normal pulmonary function. If the hemothorax is not completely drained, the patient is at risk for further interventions or even an infection in the chest. Small asymptomatic retained hemothorax (RH) can be safely managed in an outpatient setting.² However, larger or symptomatic RH requires intervention for definitive management.

A recent study completed at our institution noted a RH rate of just over 20%. All of these patients required a second procedure to drain the hemothorax. Over 75% of patients had a second chest tube placed and the remainder underwent Video Assisted Thorascopic Surgery (VATS) or thoracotomy to evacuate the retained blood. Other studies have demonstrated similar rates of retained hemothorax with benefits of early intervention, particularly VATS.^{1,3} While early intervention, including VATS, has improved outcome, rates of RH remain stable. A recent study of nearly 500 patients at our institution determined intra-thoracic positioning of chest tubes, as long as not kinked, did not affect the rate of secondary intervention for RH. This confirms the findings of a prior study done at MCW evaluating the function of chest tubes in the lung fissure.⁴ Thus while chest tube placement techniques can vary, further studies aimed at improved chest tube position would not improve clinical results.

A single small pilot looked at placement of a sterile suction catheter directly into the chest and found a decreased rate of RH.⁵ Lavage of the pleural space at the time of chest tube placement had been anecdotally noted to decrease rates of RH. Over the past several years irrigation of the chest at the time of chest tube placement has been incorporated into our clinical practice in selected patients. The process begins with standard chest tube placement at the patient bedside. Suction is then applied to the indwelling chest tube in order to evacuate the initial liquid blood. Then 1,000 mL of warmed sterile saline is placed into the thoracic cavity through the indwelling chest tube to breakup and capture any clotted blood. Finally, suction is reapplied to evacuate as much of the fluid as possible with the chest tube connected to the standard atrium setup at the

end of the procedure. Despite its use, no previous studies have investigated the success rate of pleural lavage in the setting of traumatic hemothorax. In anticipation of performing a randomized controlled trial, we recently completed a pilot study of 20 patients investigating the benefit of thoracic irrigation. This initial data is promising, showing reduction of the RH rate to 5% with no irrigation-associated complications. Given the success of the pilot trial, we are in the process of designing and funding a prospective randomized controlled trial aimed at investigating the clinical benefit of pleural lavage. We plan to enroll 150 patients and anticipate completing the study in 12–18 months. It is our hope to expand patient enrollment in this trial by performing it at multiple centers across Wisconsin. •

FOR ADDITIONAL INFORMATION on this topic, see references below, visit mcw.edu/surgery, or contact Dr. Paul at jpaul@mcw.edu, or 414-805-9420.

REFERENCES

1. Manlulu AV, Lee TW, Thung KH, Wong R, Yim AP. Current indications and results of VATS in the evaluation and management of hemodynamically stable thoracic injuries. *European Journal of Cardio-thoracic Surgery: Official Journal of the European Association for Cardio-thoracic Surgery*, 2004;25(6):1048-53.
2. Kugler NW, Milia DJ, Carver TW, O'Connell K, Paul J. Natural history of a postpull pneumothorax or effusion: observation is safe. *The Journal of Trauma and Acute Care Surgery*, 2015;78(2):391-5.
3. Heniford BT, Carrillo EH, Spain DA, Sosa JL, Fulton RL, Richardson JD. The role of thoracoscopy in the management of retained thoracic collections after trauma. *The Annals of Thoracic Surgery*, 1997;63(4):940-3.
4. Curtin JJ, Goodman LR, Quebbeman EJ, Haasler GB. Thoracostomy tubes after acute chest injury: relationship between location in a pleural fissure and function. *AJR American Journal of Roentgenology*, 1994;163(6):1339-42.
5. Ramanathan R, Wolfe LG, Duane TM. Initial suction evacuation of traumatic hemothoraces: a novel approach to decreasing chest tube duration and complications. *The American Surgeon*, 2012;78(8):883-7.

Awards and Recognition

2015 Eberbach Award Winners



Travis Webb, MD, MHPE



G. Hossein Almassi, MD

The annual Eberbach Banquet was held on June 13 to honor Department of Surgery graduating residents and recognize outstanding faculty and resident educators.

During the ceremony, the **Aprahamian Faculty Teaching Awards**, established in 1986, were presented by the graduating chief residents in recognition of two exceptional faculty teachers (one from the full-time academic faculty and one from an affiliated institution). The first of this year's winners, **Travis Webb, MD, MHPE** (Division of Trauma/CC/ACS) is a repeat winner, also having received the award in 2011. The second award recipient was **Chris Fox, MD**, Site Director at Waukesha Memorial Hospital.

G. Hossein Almassi, MD (Division of Cardiothoracic Surgery) received the **Golden Cane Award**. Established in 1987, the Golden Cane Award recognizes an exceptional educator, as chosen by junior and senior medical students. **Thomas Carver, MD** (Division of Trauma/CC/ACS) was selected by current surgery residents as the recipient of this year's **Professionalism Award**. This award, established in 2005, is presented to the faculty member who best exemplifies extraordinary professionalism.

Congratulations and thank you to these devoted educators for their dedication and contributions to the education and training of our medical students and residents.



Chris Fox, MD



Thomas Carver, MD



Ghulam Murtaza, MD

First Graduate of MCW Cardiothoracic Surgical Residency Training Program

Congratulations and best wishes to **Ghulam Murtaza, MD**, who graduated from MCW's Six-Year Integrated Cardiothoracic Surgery Residency Program in June.

Dr. Murtaza has accepted a staff surgeon position in Cardiothoracic Surgery at Dean Clinic in Madison, Wisconsin. Dr. Murtaza is the first graduate of MCW's Cardiothoracic Surgical Residency Training Program, which was initially accredited in July, 2010. Dr. Mario Gasparri serves as the Cardiothoracic Residency Program Director.

To refer a patient or request a transfer/consultation, please use the references below:

Froedtert & the Medical College of Wisconsin

All non-cancer requests
Referrals: 800-272-3666
Transfers/Consultations:
877-804-4700
mcw.edu/surgery

Clinical Cancer Center
Referrals: 866-680-0505
Transfers/Consultations:
877-804-4700

Children's Hospital of Wisconsin

Referrals/Transfers/
Consultations: 800-266-0366

Medical Ethics in the 21st Century



MARSHALL BECKMAN, MD, MA
Division of Trauma/CC/ACS

*Ethics is nothing else
than reverence for life.*

—Albert Schweitzer

The surgical realm in the 21st century is complex and changing. It would be easy to argue that decisions are more complex. We now have genetic testing and the possibility of genetic manipulation, living donor transplantation, and the myriad of other developments. These developments present a new complexity of ethical thought and difficult questions.

Some of the problems that surgeons face may never change, however. We often ask our patients and others to consider filling out paperwork for their living will (which addresses immediate end of life concerns like intubation or other life prolonging measures) or durable power of attorney for health care (which covers all health care decisions). Both will allow one to choose a surrogate decision maker in the event that one is not able to make decisions for one's self. They also document the desires of the patient in a more formal manner. We should, of course, continue to encourage our patients to communicate their wishes to us and their loved ones. Sometimes, the only thing we have left as physicians is to honor those wishes. One of the conversations that we have with a patient and their family members is whether our patients, at the end of their lives, desire aggressive treatment. Often, a question is asked about whether to be intubated or go on dialysis and a response is elicited and documented. These conversations can be expanded to discuss nursing home placement and palliative surgical procedures and beyond. Then, of course, is the age old question of whether or not to operate. Even with all the new developments, I think that question will be around for a while.

Language that is being used more and more includes words like "culturally competent care," and this comprises excellent medical care. This is part of the core competencies for surgical training and is an emphasis of the American College of Surgeons (Bulletin

of the American College of Surgeons, March 1, 2012). As part of their educational curriculum, our surgical residents have an ethics curriculum that includes case presentations. These sessions are lively and cover complex issues of resource allocation, end of life decisions and many others. This is done in conjunction with Cindy Morgenweck, MD, and Art Derse, MD, from the MCW Center for Bioethics and Humanities and is very popular with the residents.

Other ways that the MCW Department of Surgery is increasing depth of care is by involvement with palliative care. A recent surgical grand rounds presentation by Dr. Fabian Johnston in the Division of Surgical Oncology at MCW highlighted the role of the surgeon in palliative medicine and how we can expand that role. MCW has had a long tradition of robust palliative medicine and we are proud to continue that in the Department of Surgery.

In *Principles of Biomedical Ethics*, originally published in 1979, Beauchamp and Childress described four principles of bioethics: Autonomy (making decisions for oneself, free from coercion), Beneficence (weighing benefits and deficits to produce the best result), Non-maleficence (first do no harm), and Justice (equal access to resources for everyone). Despite all the recent and ongoing change in our practice, these principles will continue to apply. It will be interesting to see where the future takes us and what new questions arise. In any case, MCW Department of Surgery will be ready to answer those questions. •

AUTONOMY
BENEFICENCE
NON-MALEFICENCE
JUSTICE

FOR ADDITIONAL INFORMATION on this topic, visit mcw.edu/surgery, or contact Dr. Beckman at mbeckman@mcw.edu, or 414-805-9420. Dr. Beckman serves as the Living Donor Advocate for the Live Liver Transplant Program.

Medical College of Wisconsin – The University 2015 Endocrine Surgery Symposium



AZADEH A. CARR, MD
Division of Surgical Oncology



DOUGLAS B. EVANS, MD
Chair, Department of Surgery
Division of Surgical Oncology



TRACY S. WANG, MD, MPH
Chief, Section of Endocrine Surgery
Division of Surgical Oncology



TINA W.F. YEN, MD, MS
Division of Surgical Oncology



Elizabeth G. Grubbs, MD, MPH; Jeffrey E. Lee, MD;
Nancy D. Perrier, MD; and Paul G. Graham, MD.
Department of Surgical Oncology, M. D. Anderson
Cancer Center

The 2015 MCW – M. D. Anderson Cancer Center Endocrine Surgery Symposium was held on June 19 – 20, 2015 at the Harley-Davidson Museum® and marked the sixth year of the symposium.

The program for the annual Endocrine Surgery symposium is designed to address contemporary issues in the management of patients with surgical endocrine benign and malignant diseases. This includes thyroid, parathyroid, adrenal, neuroendocrine pancreas, and hereditary neoplasias. Didactic sessions, panel discussions, and case presentation sessions are part of the symposium. The target audience is medical professionals (physicians and allied health professionals) who care for patients with surgical endocrine disease, including general surgeons, endocrine surgeons, head and neck surgeons, endocrinologists, and primary care providers.


Speakers include multidisciplinary experts from the Medical College of Wisconsin Departments of Surgery, Medicine, Radiology, Pathology, Otolaryngology, and the Human and Molecular Genetics Center; endocrine surgeons from the Department of Surgical Oncology at the M. D. Anderson Cancer Center in Houston, Texas; and invited, nationally and internationally renowned surgeons and endocrinologists. The breadth of invited speakers highlights the importance of the multidisciplinary approach to patients with surgical endocrine disease.

This year's symposium focused on the management of patients with primary hyperparathyroidism. Invited speakers included Shonni Silverberg, MD, an

of Texas M. D. Anderson Cancer Center



Shonni Silverberg, MD



The 2015 symposium was held at Harley-Davidson Museum.®

Photo courtesy of VisitMilwaukee.com

endocrinologist from the Columbia University College of Physicians and Surgeons and Sally Carty, MD, an endocrine surgeon from the University of Pittsburgh and a recent past-President of the American Association of Endocrine Surgeons (AAES).

Past invited speakers have included:

2014

- Bryan Haugen, MD
- Sanziana A. Roman, MD
- Julie Ann Sosa, MD, MS

2013

- Erik K. Alexander, MD
- Richard T. Kloos, MD

2011

- Peter Angelos, MD, PhD

2010

- Michael J. Demeure, MD, MBA
- Sonia L. Sugg, MD
- Edwin L. Kaplan, MD
- George L. Irvin III, MD
- Herbert Chen, MD

REFERENCES

1. Silverberg SJ, Clarke BL, Peacock M, *et al.* Current issues in the presentation of asymptomatic primary hyperparathyroidism: proceedings of the Fourth International Workshop. *J Clin Endocrinol Metab*, 2014;99(10):3580-3594.
2. Bilezikian JP, Brandi ML, Eastell R, *et al.* Guidelines for the management of asymptomatic primary hyperparathyroidism: summary statement from the Fourth International Workshop. *J Clin Endocrinol Metab*, 2014;99(10):3561-3569.
3. Wang TS, Evans DB. The importance of a multidisciplinary approach to endocrine tumors. *Surgery*, 2010;148(6):1311-1312.
4. Yen TW, Evans DB. Do practice patterns reflect guidelines? *Ann Surg Oncol*, 2010;17(6):1478-1480.

FOR ADDITIONAL INFORMATION on this topic, contact Dr. Wang at tswang@mcw.edu, or 414-805-5755.



Follow us on Twitter!
@MCWEndoSurg

Get Your Rear in Gear—Visiting Professor

by Meg M. Bilicki, Director of Development for the Department of Surgery



The Division of Colorectal Surgery at the Medical College of Wisconsin, in collaboration with the Colon Cancer Coalition, has established the *Get Your Rear in Gear* Visiting Professor.

The second annual *Get Your Rear in Gear* Visiting Professor lecture on Wednesday, October 7, 2015, will feature Rodrigo O. Perez, MD, Colorectal Surgery Division, School of Medicine, University of São Paulo, São Paulo, Brazil. Dr. Perez will present "Organ Preservation in Rectal Cancer Management - The Watch and Wait Strategy."

Dr. Perez, a dedicated colorectal surgeon and researcher, is investigating new treatment strategies for rectal cancer based on scientific evidence involving the response mechanisms of rectal cancer to neoadjuvant chemoradiation therapy.

Dr. Perez received his medical degree and surgical training at the University of São Paulo School of Medicine in Brazil, where he joined a team of surgeons led by the world-renowned pioneer in colorectal surgery, Professor Angelita Harb-Gama. Dr. Harb-Gama's team is conducting innovative research related to the treatment of rectal cancer.

He was awarded a prestigious grant by the São Paulo Research Foundation to study the clinical, surgical and bio-molecular features of tumors that may respond completely to chemoradiation therapy. These contributions have been significant to the development of alternative treatment strategies to patients with rectal cancer.

Dr. Perez also joined the Ludwig Institute for Cancer Research in São Paulo, where he collaborates with scientists in an effort to provide clinically relevant genetic testing and monitoring of patients with rectal cancer. His numerous contributions to high-impact, peer-reviewed scientific journals have been consistently cited and received awards in national and international meetings. In 2010, he was appointed to the Editorial Board of the journal *Diseases of the Colon & Rectum*. In 2014, Dr. Perez and his group received the 2013 Impact Paper of the Year Award.

Proceeds from the annual *Get Your Rear in Gear* Milwaukee 5K Run/Walk will support hosting a distinguished surgeon in the field of colorectal cancer to present a lecture on the latest clinical and basic science research.



2015 Get Your Rear in Gear Milwaukee 5K Run/Walk
Saturday, October 10, 2015
Rotary Performance Pavilion at Hart Park
Register online at:
www.getyourrearingear.com/milwaukee

The 2015 *Get Your Rear in Gear* Milwaukee 5K Run/Walk will be held on Saturday, October 10, at the Rotary Performance Pavilion at Hart Park in Wauwatosa. Since 2011, the event has raised \$60,000 to support MCW programs for colon cancer research, education, prevention, and screening, as well as the *Get Your Rear in Gear* Visiting Professor. Colon cancer claims more than 54,000 lives in the U.S. every year. One in 20 people is expected to develop colorectal cancer in their lifetime.

"We are grateful to the many event participants and volunteers for making this lecture possible. We believe it will be very beneficial in increasing knowledge and helping to ensure the prompt diagnosis and treatment of colon and rectal cancer for patients and their families," said Dr. Kirk Ludwig. •

FOR MORE INFORMATION on the *Get Your Rear in Gear* Milwaukee 5K Run/Walk, please contact Lynn Dickinson at (414) 805-1690 or ldickinson@mcw.edu.

THE MEDICAL COLLEGE OF WISCONSIN **DEPARTMENT OF SURGERY**

FACULTY BY SPECIALTY

Bariatric and Minimally Invasive Surgery

Matthew I. Goldblatt, MD
Jon C. Gould, MD
Andrew S. Kastenmeier, MD*
Tammy L. Kindel, MD, PhD
James R. Wallace, MD, PhD

Breast Surgery

Amanda L. Kong, MD, MS
Miraj Shah-Khan, MD*
Alonzo P. Walker, MD
Tina W.F. Yen, MD, MS

Cardiac Surgery

G. Hossein Almassi, MD
R. Eric Lilly, MD*
Michael E. Mitchell, MD
Zahir A. Rashid, MD
Chris K. Rokkas, MD
Ronald K. Woods, MD, PhD

Colorectal Surgery

Kirk A. Ludwig, MD*
Mary F. Otterson, MD, MS
Carrie Y. Peterson, MD
Timothy J. Ridolfi, MD

Endocrine Surgery

Azadeh A. Carr, MD*
Douglas B. Evans, MD*
Tracy S. Wang, MD, MPH*
Stuart D. Wilson, MD
Tina W.F. Yen, MD, MS

General Surgery

Marshall A. Beckman, MD, MA*
Kathleen K. Christians, MD
Lucia Chou, MD
Panna Codner, MD
Christopher Dodgion, MD, MSPH, MBA
Matthew I. Goldblatt, MD
Jon C. Gould, MD

General Surgery, cont.

Jeremy S. Juern, MD
Andrew S. Kastenmeier, MD*
Tammy L. Kindel, MD, PhD
Dean E. Klinger, MD*
Todd A. Neideen, MD
Philip N. Redlich, MD, PhD
Lewis B. Somberg, MD
Gordon L. Telford, MD
James R. Wallace, MD, PhD
Travis P. Webb, MD, MHPE
John A. Weigelt, MD, DVM, MMA

Pediatric General and Thoracic Surgery

John J. Aiken, MD*
Marjorie Arca, MD*
Casey M. Calkins, MD*
John C. Densmore, MD*
David M. Gourlay, MD*
Tammy L. Kindel, MD, PhD
Dave R. Lal, MD, MPH*
Keith T. Oldham, MD*
Thomas T. Sato, MD*
Amy J. Wagner, MD*

Research Faculty

John E. Baker, PhD
Laura D. Cassidy, PhD, MS
Charles E. Edmiston, Jr., MS, PhD, CIC
Mats Hidestrand, PhD
Michael A. James, PhD
Muthusamy Kunnimalaiyaan, PhD
Qing Miao, PhD
Aoy T. Mitchell, PhD
Kirkwood Pritchard, Jr., PhD
Parvaneh Rafiee, PhD
Mary Shimoyama, PhD
Toku Takahashi, MD, PhD
Hao Zhang, PhD

Surgical Oncology

Azadeh A. Carr, MD*
Kathleen K. Christians, MD
Douglas B. Evans, MD*
T. Clark Gamblin, MD, MS
Fabian Mc. Johnston, MD, MHS*
Johnny C. Hong, MD
Amanda L. Kong, MD, MS
Edward J. Quebbeman, MD, PhD
Miraj Shah-Khan, MD*
Susan Tsai, MD, MHS
Kiran K. Turaga, MD, MPH
Alonzo P. Walker, MD
Tracy S. Wang, MD, MPH*
Stuart D. Wilson, MD
Tina W.F. Yen, MD, MS

Thoracic Surgery

Mario G. Gasparri, MD
George B. Haasler, MD
David W. Johnstone, MD*

Transplant Surgery

David C. Cronin, II, MD, PhD
Johnny C. Hong, MD
Christopher P. Johnson, MD
Joohyun Kim, MD, PhD
Abbey R. Kruper, PsyD
Allan M. Roza, MD
Stephanie Zanolowski, PhD
Michael A. Zimmerman, MD

Trauma/CC/ACS

Marshall A. Beckman, MD, MA*
Thomas Carver, MD
Lucia Y. Chou, MD
Panna A. Codner, MD
Terri A. deRoos-Cassini, PhD
Christopher M. Dodgion, MD,
MSPH, MBA
Jeremy S. Juern, MD

Trauma/CC/ACS, cont.

David J. Milia, MD*
Todd A. Neideen, MD
Jasmeet S. Paul, MD
Lewis B. Somberg, MD
Travis P. Webb, MD, MHPE
John A. Weigelt, MD, DVM, MMA

Vascular Surgery

Kellie R. Brown, MD
C.J. Lee, MD
Brian D. Lewis, MD
Michael J. Malinowski, MD
Peter J. Rossi, MD*
Gary R. Seabrook, MD

Affiliated Institution Program Directors

Steven K. Kappes, MD
Aurora - Grafton
Alysandra Lal, MD
Columbia St. Mary's Hospital
Joseph C. Battista, MD
St. Joseph's Hospital
Christopher J. Fox, MD
Waukesha Memorial Hospital

Chief Surgical Residents (2015–2016)

Ahmed Ali, MD
Betsy Appel, MD
Ryan Berg, MD
Nathan Heinzerling, MD
Kevin Hudak, MD
Abby Rothstein, MD
Kathleen Simon, MD

* Also participates in Community Surgery/Off-campus locations.

LEARN MORE AT MCW.EDU/SURGERY



Department of Surgery
9200 West Wisconsin Avenue
Milwaukee, WI 53226

MARK YOUR CALENDARS

Upcoming Events

October 1-2: Pierre-Alain Clavien, M.D. (University Hospital, Zurich) – 29th Annual C. Morrison Schroeder Visiting Professor— in conjunction with the 3rd Annual Solid Organ Transplantation Research Symposium

Medical College of Wisconsin

October 7: Rodrigo Perez, M.D. — *Get Your Rear In Gear* Visiting Professor

October 10: *Get Your Rear in Gear*, Run/Walk for Colon Cancer Prevention

Hart Park, Wauwatosa

October 22: Vascular Access Symposium

Medical College of Wisconsin

October 23: Fall Research Symposium

Medical College of Wisconsin

October 30: Aortic Dissection Symposium

Medical College of Wisconsin

November 19: Surgical Site Infection Summit

Crowne Plaza, Madison

Please contact Heidi Brittnacher (hbrittna@mcw.edu) for more information on any of these events.

Department of Surgery

*Dedicated to Clinical Care,
Research and Education*

- Cardiothoracic Surgery
- Colorectal Surgery
- Community Surgery
- Surgical Education
- General Surgery
- Pediatric Surgery
- Surgical Oncology
- Transplant Surgery
- Trauma/CC/ACS
- Vascular Surgery

Leading the Way is published three times yearly by The Medical College of Wisconsin – Department of Surgery, 9200 W. Wisconsin Ave., Milwaukee, WI 53226 © 2015.

Editors:

Amy Wagner, MD

Heidi Brittnacher, 414-805-9427 or
hbrittna@mcw.edu

Amy Leisten, MS, 414-805-8620 or
aleisten@mcw.edu.

Leading the Way is written for physicians for medical education purposes only. It does not provide a complete overview of the topics covered and should not replace the independent judgment of a physician about the appropriateness or risks of a procedure for a given patient.